

# The Combined Use of All-Ceramic and Conventional Metal-Ceramic Restorations in the Rehabilitation of Severe Tooth Wear

Davide Cortellini, Dr Odont, Dr Med Dent\*

Angelo Canale, CDT\*\*

Angela Giordano, CDT\*\*

Barbara Bergantini, CDT\*\*

Daniela Bergantini, CDT\*\*

**N**atural appearance, vitality, and excellent esthetics represent the major requests of contemporary dental patients. Evolving trends in treatment approach and in dental materials have allowed clinicians to provide a wider range of therapeutic options.

All-ceramic restorations, besides being the treatment of choice in visible areas, are becoming more commonly used in the posterior regions. In fact, material development and technique improvements during the last few years have increased the predictability of the new all-ceramic systems for both anterior and posterior sites.<sup>1,2</sup>

These newly developed restorations, applied in appropriate cases, besides resulting in a superior esthetic appearance, may provide important ad-

vantages such as simplification of the clinical procedure and supragingival margins that allow for the maintenance of periodontal health over longer periods of time. Furthermore, the possibility of using etchable ceramics in conjunction with the adhesive cementation technique on composite buildups provides significantly higher retention.<sup>3,4</sup> While there is currently a lack of scientific evidence to fully support this technique long-term, the need for crown-lengthening procedures in the presence of a shorter natural abutment may be reduced, thus permitting a more conservative treatment approach.<sup>5</sup>

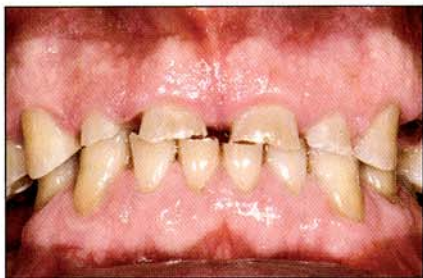These characteristics are particularly indicated for the treatment of some types of advanced hard tissue lesions that compromise tooth anatomy, function, and esthetics in the presence of intact periodontal support. More and more, contemporary dentistry is facing complex restorative cases of tooth wear<sup>5</sup> because this pathology is increasingly prevalent.

Noncarious tooth surface loss is a physiologic process that occurs throughout life<sup>6</sup>; however, various conditions may lead to pathologic extensive

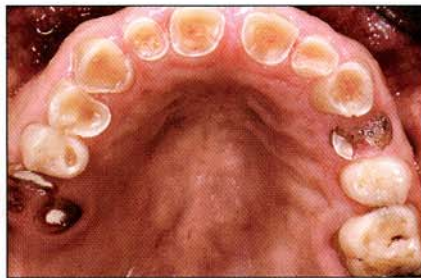\* Private practice, Riccione, Italy.

\*\* Dental laboratory technician, Rimini, Italy.

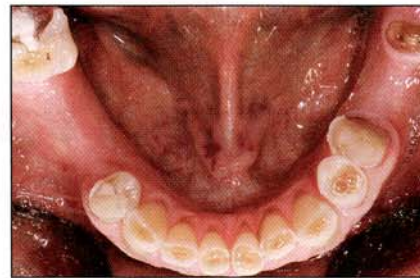
**Correspondence to:** Dr Davide Cortellini, Via I. Nievo II, 47838 Riccione, Italy. E-mail: dc@davidecortellini.191.it



**Fig 1** Initial situation, frontal view. The protruded position of the mandible and the reduction of the vertical dimension of occlusion are evident.



**Fig 2** Occlusal view of the maxilla. Pulp is nearly exposed.



**Fig 3** Occlusal view of the mandible. Posterior teeth are missing.

tooth wear.<sup>7</sup> Loss of tooth structure is often a combination of various etiologic factors, as in the clinical case presented here, and may result from attrition, abrasion, abfraction, and erosion.<sup>8</sup> *Attrition* is loss of dental structure due to tooth-to-tooth contact, while *abrasion* is normally caused by foreign objects. *Abfraction* can be defined as the formation of cervical abrasive lesions resulting from the action of occlusal interference and stress. *Erosion* is defined as "the progressive loss of tooth substance by chemical processes that do not involve bacterial action."<sup>9</sup> The mechanisms that lead to erosion are related to exposure to acids both extrinsic (acidic beverages, foods,<sup>10</sup> and medications) and intrinsic (vomiting and regurgitation associated with gastrointestinal disorders including gastroesophageal reflux<sup>11,12</sup>; hiatus hernia; duodenal ulcers<sup>13</sup>; and eating disorders, ie, anorexia<sup>14</sup> and bulimia<sup>15</sup>).

## CASE PRESENTATION

A 50-year-old male patient complained of severe wear, difficulty in mastication, and extremely poor dental esthetics (Figs 1 to 3). The patient reported a history of gastroesophageal disease, diagnosed 3 years prior to the first dental examination, although the onset was probably several years earlier. Dietary analysis revealed no consumption of acidic beverages. He was not seen by a dental practitioner during the preceding 5 years.

## Clinical Examination

Extraoral examination did not reveal any abnormality or asymmetry. During mandibular opening, a "click" localized at both sides, left and right, could be detected, but extreme mandibular movements were feasible, and the patient did not report any pain at the temporomandibular joint (TMJ) sites.

Intraoral examination revealed deep erosive lesions. Wear was mainly localized in the anterior teeth. "Cupping" of the maxillary and mandibular anterior teeth was evident with nearly complete exposure of the pulp (see Figs 2 and 3). A significant reduction of the vertical dimension of occlusion (VDO), detectable by an increased freeway space and an alteration of the patient's profile at the position of maximal intercuspation, was present. Loss of VDO was partly because of the erosive process, but mainly a result of the absence of posterior teeth due to previous incongruous treatments.

In particular, the maxillary right second and third molars and mandibular left first molar and right second premolar and first and third molars were missing; the maxillary left first premolar and second and third molars and mandibular left second and third molars were lost since only a portion of the roots was left; and the maxillary right first molar and mandibular right second molar had compromised restorations.

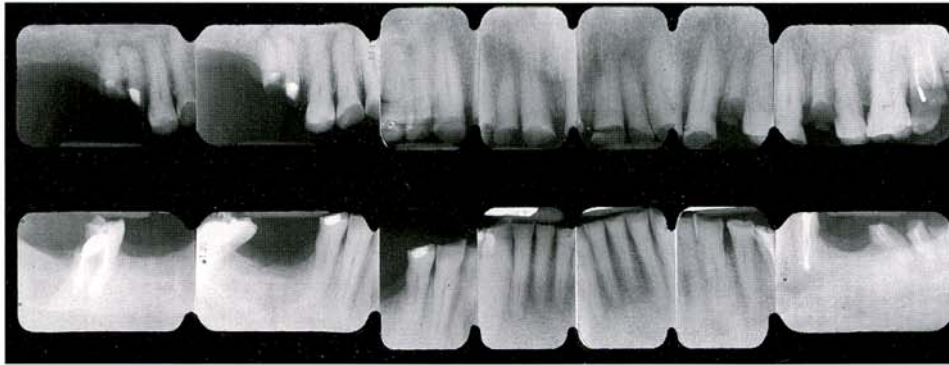


Fig 4 Full-mouth radiographs.

The present clinical condition and the severe degree of tooth wear resulted from a combination of different etiologic factors:

- Erosion due to gastroesophageal disease
- Loss of posterior teeth due to previous incongruous dental treatments
- Loss of vertical dimension and sliding of the mandible toward a protruded position, with maxillary and mandibular anterior teeth contact (attrition)
- Lack of incisal and canine guidance and presence of parafunctional habits

Esthetic evaluation revealed a gummy smile with symmetry of the gingival margins. There was no evidence of periodontal disease, and the patient's oral hygiene was good.

### *Radiographic Evaluation*

A significant loss of enamel with near pulpal exposure was present on the maxillary anterior teeth (Fig 4). All the anterior teeth were vital in both arches. The root canals of the mandibular left second premolar and right second molar were treated. The roots of the maxillary right first molar presented periapical lesions. The radiographic examination clearly confirmed the loss of the teeth mentioned in the previous section. No radiologic signs of periodontal disease could be detected.

Bone resorption was only present at sites of missing and/or lost teeth.

### *Treatment Planning*

The first step of the treatment plan included control of the reflux disease. The patient was sent to a gastroenterologist for medical treatment to prevent further damage to his dentition and to improve his general health condition. Systemic treatment with Lansoprazole associated with antibiotic therapy was prescribed by the gastroenterologist. The efficacy of the therapy was assessed by monitoring the variation of esophageal pH.

A complex prosthetic rehabilitation was then proposed to the patient, who was asking for a stable result with a high level of esthetics. In order to establish the treatment plan, all natural teeth were placed in one of three categories, based on their clinical condition and their potential to be incorporated in the definitive reconstruction: good, guarded or poor, and hopeless (Table 1). Then, based on the clinical and radiographic data, a diagnostic waxup was prepared to re-create normal tooth morphology and proportion, to achieve an acceptable occlusal scheme, and to develop an appropriate prosthetic treatment plan (Fig 5).

The treatment plan was designed to simplify the therapeutic approach and reduce morbidity and financial costs by combining traditional prosthetic procedures with more innovative solutions.

**Table 1** Prognosis of natural teeth prior to treatment\*

	X	X	3 (16)	4 (15)	5 (14)	6 (13)	7 (12)	8 (11)	9 (21)	10 (22)	11 (23)	12 (24)	13 (25)	14 (26)	15 (27)	16 (28)
Hopeless												•			•	•
Guarded or poor			•													
Good				•	•	•	•	•	•	•	•		•	•		
Good					•	•	•	•	•	•	•	•				
Guarded or poor		•											•			
Hopeless															•	
	X	31 (47)	X	X	28 (44)	27 (43)	26 (42)	25 (41)	24 (31)	23 (32)	22 (33)	21 (34)	20 (35)	X	18 (37)	X

\*Tooth numbers: Universal system (Fédération Dentaire Internationale [FDI] system).

Fixed partial dentures were selected as a relatively noninvasive option, thus avoiding advanced implant therapy with regeneration procedures at the mandibular right second premolar–first molar and maxillary left first premolar areas, where a thin bone crest was present. Furthermore, as requested by the patient, maintenance of the mesiobuccal and palatal roots of the maxillary right first molar was chosen rather than opting for a sinus lift procedure necessary for implant placement at that site. A single wide-diameter implant was planned to replace the mandibular left first molar.

The elements labeled *hopeless* were planned for extraction. Root canal treatments were planned for the maxillary central and lateral incisors (*good* category) because of the near pulp exposure and to allow adequate retention of the buildup material using fiber posts (Figs 6 and 7). Endodontic re-treatment and fiber post composite buildups were planned for the mandibular left second premolar and right second molar and for the mesiobuccal and palatal roots of the maxillary right first molar (*guarded or poor* category). The remaining teeth demonstrated sufficient crown integrity and adequate wall height to allow for the

preservation of pulp vitality; therefore, adhesive buildups were planned, where needed, in order to obtain correct proportions of the preparations.

Based on the diagnostic waxup, a silicone template was fabricated to be used as a reference guide both for the buildups as well as during preliminary preparations (Fig 8).

Since the periodontal support was intact and 2 to 3 mm of healthy dentin would be present apical to the limit of the resin buildup, surgical crown lengthening was not initially planned, and the hypothesis to use etchable all-ceramic crowns in conjunction with an adhesive technique was considered to compensate for possible insufficient wall height for conventional porcelain-fused-to-metal restorations. This approach, in addition to preserving intact periodontal support, would enhance an optimal esthetic result for the translucent quality of these restorations.

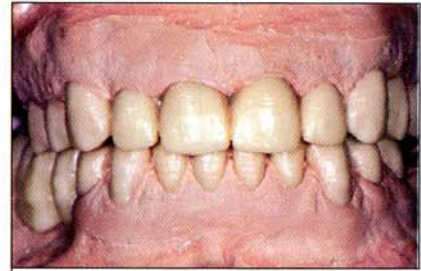### Restorative Sequence

Two full-arch provisional fixed partial dentures were manufactured by the laboratory according to the diagnostic waxup, taking into account the ob-

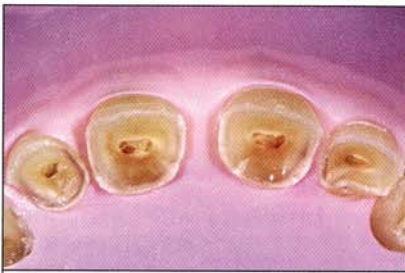**Fig 5** Diagnostic waxup.

**Figs 6 and 7** Endodontic treatment and composite core buildups with fiber posts in the maxillary anterior teeth.

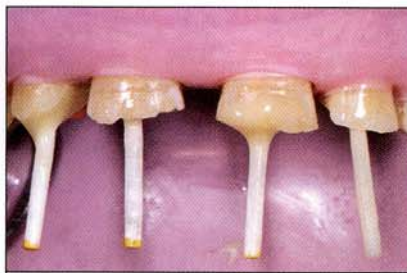**Fig 8** Preliminary preparation using the silicone template.



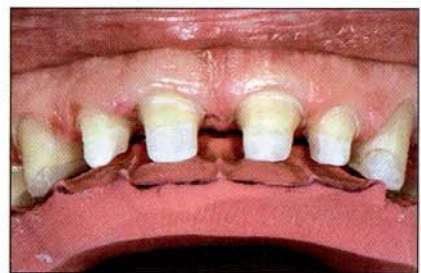5



6



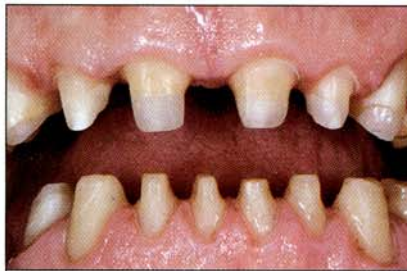7



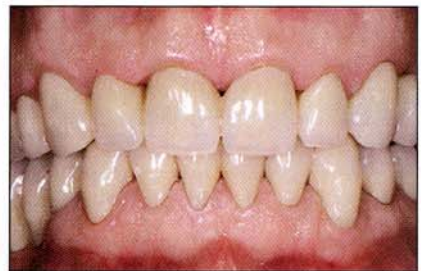8

**Fig 9** Interocclusal space at the new vertical dimension of occlusion.

**Fig 10** Provisional placement. The increase in the vertical dimension of occlusion is evident.



9



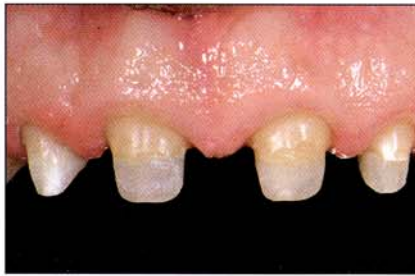10

tained increase in the VDO. The amount of increase in the VDO was obtained by means of the diagnostic waxup recording three waxes of central relation with an acceptable patient's profile. Tolerance of the new VDO by the patient would be tested during the 6 months of the provisional phase. The incisal and canine guidance tables were fabricated to reproduce the protrusive and excursive movements.

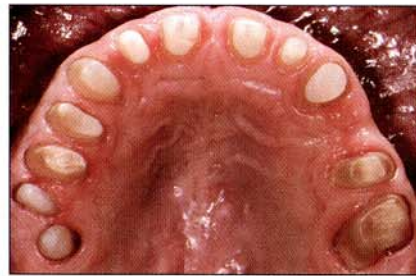The patient was seen initially for endodontic treatment and extractions. Composite core buildups with fiber posts and preliminary preparations (using the silicone template) (see Figs 6 to 8) and provisional placement were completed in one appointment in order to achieve the planned increase in the vertical dimension of occlusion and to provide occlusal stability (Fig 9). The provisional

restorations were relined and adjusted to achieve a stable occlusion at the planned vertical dimension with correct protrusive and lateral movements. A noneugenol temporary cement was used for the cementation (Fig 10). The patient was re-examined a few days later to further refine the occlusion.

During the provisional phase, a single wide-diameter implant was placed in the area of the mandibular left first molar. Provisional restorations were left in function for 6 months, and the patient was reviewed monthly to evaluate the condition of the provisional fixed partial dentures, to monitor the extent of wear, and to check the occlusion and eventual symptoms at the TMJs. The provisional restorations also provided important information concerning tooth shape and proportions,



**Fig 11** Final preparations of the maxillary incisors.



**Fig 12** Occlusal view of the final preparations of the maxillary teeth.

esthetic appearance, and phonetics to allow the clinician and the dental technician to make any necessary changes before the fabrication of the final restorations.

After the completion of the provisional phase, a second re-evaluation was performed in order to check the outcome of the endodontic treatment and to confirm the final prosthetic scheme. At the 6-month re-evaluation, no significant signs of abrasion of the provisional crowns were noted, and the patient found the fixed partial dentures comfortable and did not report any symptoms at the TMJs, meaning that the new mandibular position had been well tolerated. The radiographic examination revealed a reduction of the periapical lesions of the treated teeth.

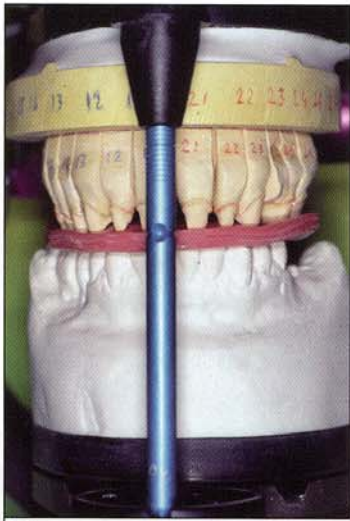Etchable all-ceramic crowns (Empress 2 and Eris, Ivoclar Vivadent, Schaan, Liechtenstein) were chosen for all anterior and single natural posterior elements. Traditional metal-ceramic fixed partial dentures were planned to restore the mandibular right second premolar and first molar and the implant in the mandibular left first molar area, as well as to splint the hemisected maintained roots of the maxillary right first molar and second premolar. An Empress 2 fixed partial denture was chosen for the maxillary left canine to second premolar region, taking into consideration both the high visibility of this site, emphasized by the patient's gummy smile, and the presence of sufficient space to create adequate connector height.

Final preparations were then performed according to the specific guidelines for the different

types of restorations. Teeth to be restored with all-ceramic crowns were prepared with a rounded chamfer (1.0 mm). Where tooth dimension did not allow the creation of deep preparations, such as in mandibular anterior teeth, mini-chamfers were performed. An advantage of the all-ceramic crown system used in this case compared with porcelain-fused-to-metal crowns is that, even in the presence of limited space, excellent esthetic results can be obtained because an opaque layer masking the underlying metal substructure is not required. An occlusal clearance of 1.5 to 2 mm in both the maxillary and mandibular arches (totalling 3 to 4 mm at the predefined vertical dimension of occlusion) was left for the opposing teeth. It should be noted that, due to the increase of the vertical dimension of occlusion, the required interocclusal space was obtained by building up the natural teeth rather than by further reducing the tooth height (see Fig 9).

Particular care was taken to ensure the creation of smooth, rounded, and precise preparation surfaces to avoid stress concentration on internal contact points (Figs 11 and 12). The possibility to allocate the margins at the gingival level facilitated tooth preparation and the final impression. The hemisected roots and the teeth to be restored with a metal-ceramic fixed partial denture were prepared with a knife-edge margin.

Final impressions were performed using a polyether impression material in custom trays. A single silk retraction cord was placed in the gingival sulcus before impressions were made.

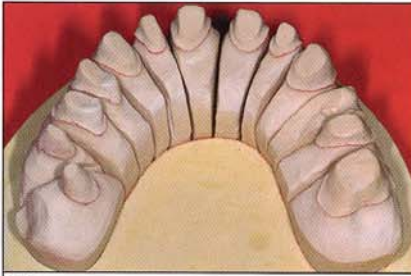


13

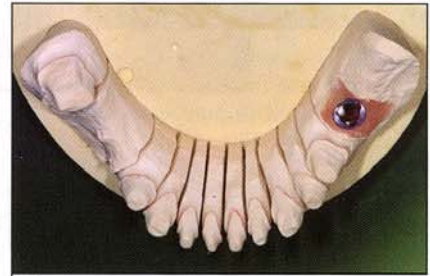**Fig 13** To cross-mount the casts of the provisional restorations against the tooth preparations, three centric waxes were recorded between the prepared teeth on one arch and the provisional fixed partial dentures on the opposite arch.

**Fig 14** Cast of the definitive preparations of the maxilla.

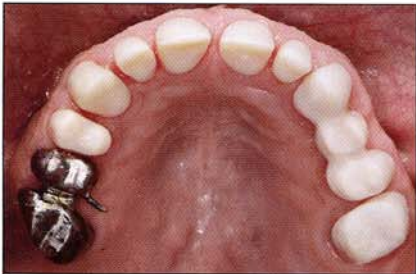**Fig 15** Cast of the definitive preparations of the mandible.



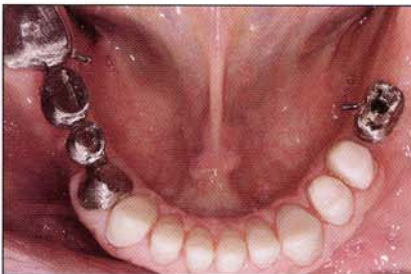14



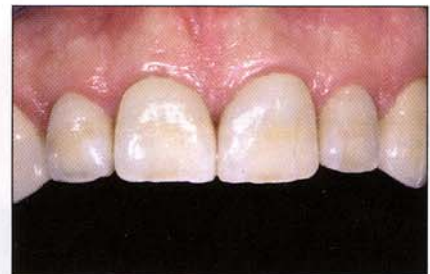15



16



17

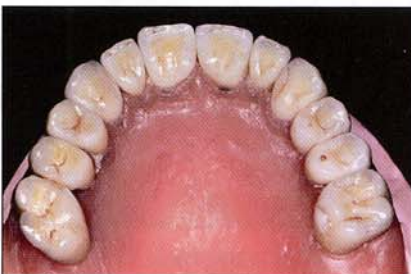

18

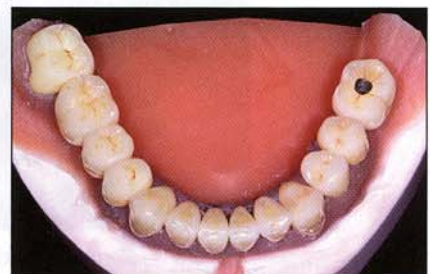**Figs 16 and 17** The adaptation and fit of the substructures were checked using a silicone paste.

**Fig 18** Trial of the metal substructures and ceramic cores (Empress 2).

**Fig 19** Maxillary restorations completed on a soft tissue cast.



19



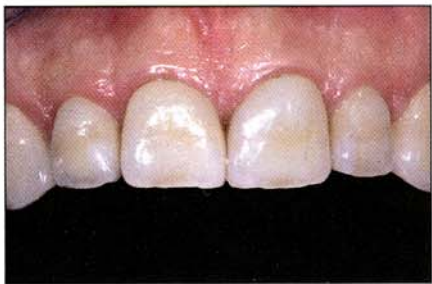20

**Fig 20** Mandibular restorations completed on a soft tissue cast.

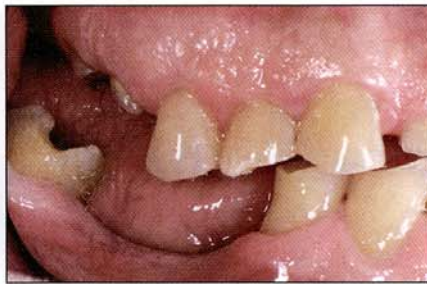A facebow transfer was used to mount the maxillary cast on a fully adjustable articulator. The jaw positions were recorded in centric relation using three interocclusal waxes between the prepared teeth of the maxillary and mandibular arches. To cross-mount the casts of the provisional restorations against the tooth preparations, three centric waxes were recorded between the prepared teeth on one arch and the provisional fixed partial dentures on the opposite arch (Fig 13). This important step allows the technician to use all the

information obtained from the provisional fixed partial dentures for the fabrication of the definitive restorations, including tooth shape, proportions, esthetics, and above all the anterior determinants to be set on the articulator.

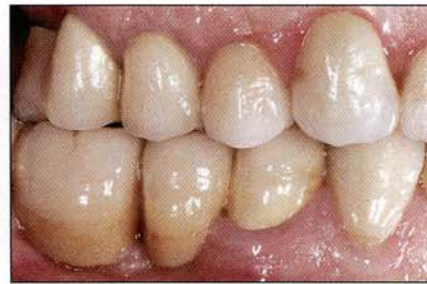The laboratory fabricated the metal substructures and the ceramic cores. The adaptation and fit of the substructures were checked using a silicone paste (Figs 14 to 18). The ceramic veneering was completed on a soft tissue cast (Figs 19 and 20). Metal-ceramic fixed partial dentures were tradi-



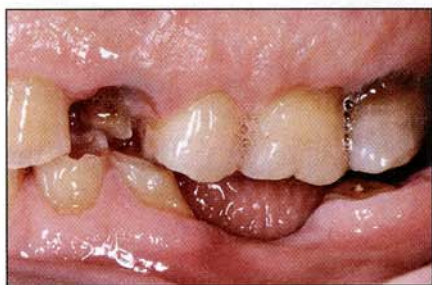**Fig 21** The cemented all-ceramic crowns. Note the supragingival placement of the margins.



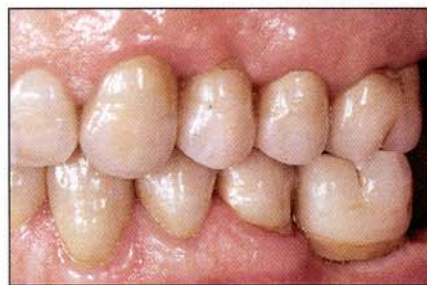**Fig 22** Lateral view of the left side before treatment.



**Fig 23** Lateral view of the left side after treatment.



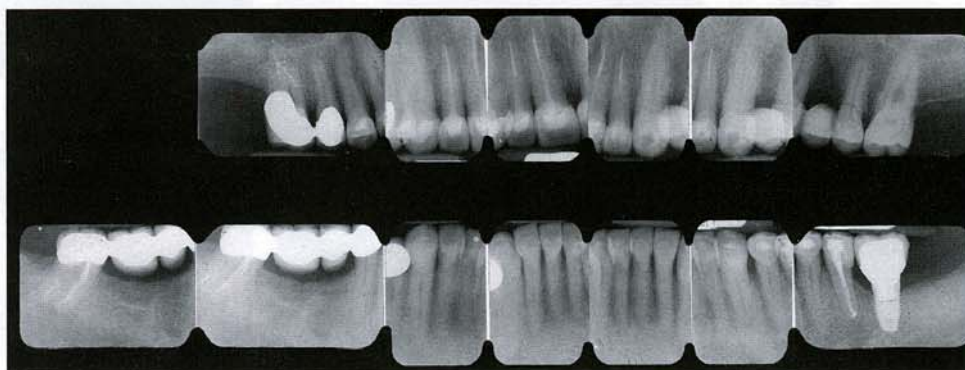
24



25

**Fig 24** Lateral view of the right side before treatment.

**Fig 25** Lateral view of the right side after treatment. Masticatory function has been restored in the posterior sites.



**Fig 26** Full-mouth radiographs after treatment.

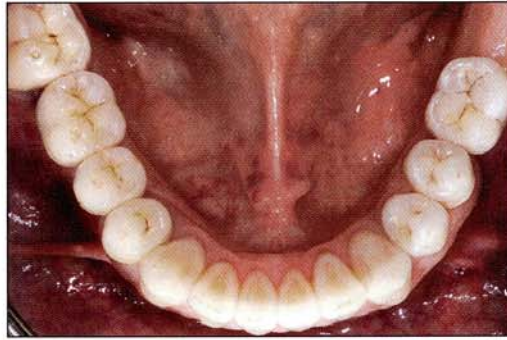
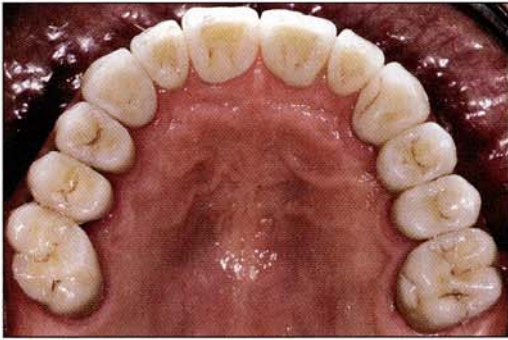
tionally cemented using a glass-ionomer cement, while for the ceramic restorations an adhesive technique was selected.

The ceramic cores were etched with 9.6% hydrofluoric acid for 1 minute and then rinsed. A silane was then applied on the internal surface. The teeth were etched with 37% phosphoric acid for 15 seconds, and a dentin adhesive was placed on the tooth surfaces. The crowns were cemented using a low-viscosity dual-cure resin cement. Thin retraction cord (3-0) was placed subgingivally to provide better control of the crown margin and to

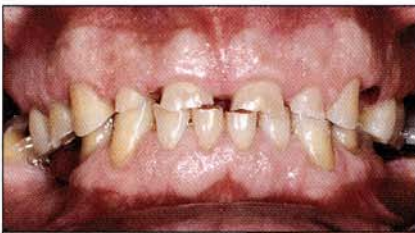facilitate cement removal. To eliminate excess cement, a finishing strip was gently passed interproximally. The implant crown was screwed directly on the implant head.

Occlusal equilibration was carried out at 1 week, 1 month, and 3 months postdelivery. Only slight occlusal adjustments were necessary to eliminate any lateral interference. The patient was very satisfied with the natural appearance of his restorations and experienced a high level of comfort in both mastication and speech (Figs 21 to 30).



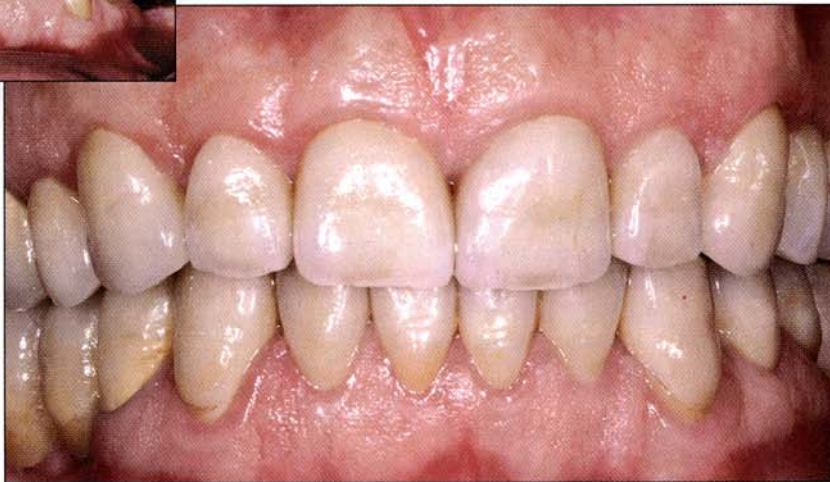

Figs 27 and 28 Occlusal views after prosthetic treatment.



29

Figs 29 and 30 Frontal views before and after therapy. Note the natural appearance of the all-ceramic crowns and the good periodontal health obtained as a result of the supragingival margins. Regrowth of the interdental papillae between the maxillary incisors is also evident.



30

## CONCLUSIONS

This case of rehabilitation of a severely worn dentition shows the usage of different restorative materials—both all-ceramic<sup>16–19</sup> and metal-ceramic—to re-create ideal health, function, and esthetics. Clinically sound advantages may be provided by using all-ceramic restorations both in anterior and posterior sites. Vast scientific evidence supports the supragingival placement of margins for prosthetic crowns.<sup>20–23</sup> Extragingival margins obtained using all-ceramic crowns also contribute to simplification of the clinical procedure and maintenance care for the patient. Furthermore, with the introduction of the latest dentin bonding systems, a predictable and strong adhesive bond can be cre-

ated between the pretreated tooth surface and the ceramic restoration,<sup>3,24,25</sup> limiting in some cases the need for crown-lengthening procedures.

Severely eroded dentitions are often found in younger patients, who generally have high esthetic expectations. In most cases, an optimal periodontal condition is present, and therapy should be aimed at the reconstruction of the tooth anatomy, possibly preserving the pulp vitality and integrity of the periodontium. In such clinical situations, all-ceramic restorations may represent a more appropriate treatment choice versus a traditional approach, which could involve systematic root canal treatment, surgical crown-lengthening procedures, and placement of metal-ceramic crowns.

Various scientific investigations have analyzed the mechanical properties,<sup>2,26</sup> marginal fit,<sup>27,28</sup> and translucency<sup>29</sup> of the all-ceramic system used in the case presented here and have shown optimal results. However, the limit of the majority of these in vitro studies is that fatiguing of the materials under the physiological condition of mastication was not examined.

To obtain reliable data on long-term success, prospective controlled clinical trials are needed. Since the introduction and use of new types of all-ceramic systems are very recent, there are, to date, few long-term clinical trials<sup>30-34</sup>; however, additional studies on long-term data will surely be welcome in the future.

## REFERENCES

- Fradeani M. The application of all-ceramic restorations in the anterior and posterior regions. *Pract Proced Aesthet Dent* 2003;Suppl:13-17.
- Pallis K, Griggs JA, Woody RD, Guillen GE, Miller AW. Fracture resistance of three all-ceramic restorative systems for posterior applications. *J Prosthet Dent* 2004;91:561-569.
- McComb D. Adhesive luting cements—Classes, criteria, and usage. *Compend Contin Educ Dent* 1996;17:759-762.
- Touati B, Quintas AF. Aesthetic and adhesive cementation for contemporary porcelain crowns. *Pract Proced Aesthet Dent* 2001;13:611-620.
- Cortellini D, Parvizi A. Rehabilitation of severely eroded dentition utilizing all-ceramic restorations. *Pract Proced Aesthet Dent* 2003;15:275-282.
- Flint S, Scully C. Orofacial age changes and related disease. *Dent Update* 1988;15:337-342.
- Smith BG, Knight JK. An index for measuring the wear of teeth. *Br Dent J* 1984;156:435-438.
- Bishop K, Kelleher M, Briggs P, Joshi R. Wear now? An update on the etiology of tooth wear. *Quintessence Int* 1997;28:305-313.
- The glossary of prosthodontic terms. *J Prosthet Dent* 1999;81:39-110.
- Fuller JL, Johnson WW. Citric acid consumption and the human dentition. *J Am Dent Assoc* 1977;95:80-84.
- Bartlett DW, Evans DF, Smith BG. The relationship between gastro-oesophageal reflux disease and dental erosion. *J Oral Rehabil* 1996;23:289-297.
- Stephan AD. Diagnosis and dental treatment of a young adult patient with gastroesophageal reflux: A case report with 2-year follow-up. *Quintessence Int* 2002;33:619-626.
- Levitch LC, Bader JD, Shugars DA, Heymann HO. Non-carious cervical lesions. *J Dent* 1994;22:195-207.
- Hurst PS, Lacey JH, Crisp AH. Teeth, vomiting and diet: A study of the dental characteristics of seventeen anorexia nervosa patients. *Postgrad Med J* 1977;53:298-305.
- Rytomaa I, Jarvinen V, Kanerva R, Heinonen OP. Bulimia and tooth erosion. *Acta Odontol Scand* 1998;56:36-40.
- Culp L. Empress 2. First year clinical results. *J Dent Technol* 1999;16(2):12-15.
- Fischer H, Marx R. Mechanische Eigenschaften von Empress 2. Interner Bericht für Ivoclar AG, 1998.
- Kappert HF. Empress Brücke / in-vitro Studie. Untersuchungsbericht an Ivoclar AG, Schaan, January 1998.
- Sorensen JA, Cruz M, Mito WT, Raffainer O, Meredith HR, Foser HP. A clinical investigation on three-unit fixed partial dentures fabricated with a lithium disilicate glass-ceramic. *Pract Periodontics Aesthet Dent* 1999;11:95-106.
- Reitemeier B, Hansel K, Walter MH, Kastner C, Toutenburg H. Effect of posterior crown margin placement on gingival health. *J Prosthet Dent* 2002;87:167-172.
- Smukler H, Chaibi M. Periodontal and dental considerations in clinical crown extension: A rational basis for treatment. *Int J Periodontics Restorative Dent* 1997;17:464-477.
- Freilich MA, Niekrash CE, Katz RV, Simonsen RJ. Periodontal effects of fixed partial denture retainer margins: Configuration and location. *J Prosthet Dent* 1992;67:184-190.
- Reeves WG. Restorative margin placement and periodontal health. *J Prosthet Dent* 1991;66:733-736.
- Gu XH, Kern M. Marginal discrepancies and leakage of all-ceramic crowns: Influence of luting agents and aging conditions. *Int J Prosthodont* 2003;16:109-116.
- Blatz MB, Sadan A, Kern M. Resin-ceramic bonding: A review of the literature. *J Prosthet Dent* 2003;89:268-274.
- Albakry M, Guazzato M, Swain MV. Biaxial flexural strength, elastic moduli, and x-ray diffraction characterization of three pressable all-ceramic materials. *J Prosthet Dent* 2003;89:374-380.
- Yeo IS, Yang JH, Lee JB. In vitro marginal fit of three all-ceramic crown systems. *J Prosthet Dent* 2003;90:459-464.
- Stappert CF, Dai M, Chitmongkolsuk S, Gerds T, Strub JR. Marginal adaptation of three-unit fixed partial dentures constructed from pressed ceramic systems. *Br Dent J* 2004;196:766-770.
- Heffernan MJ, Aquilino SA, Diaz-Arnold AM, Haselton DR, Stanford CM, Vargas MA. Relative translucency of six all-ceramic systems. Part II: Core and veneer materials. *J Prosthet Dent* 2002;88:10-15.
- Blatz MB. Long-term clinical success of all-ceramic posterior restorations. *Quintessence Int* 2002;33:415-426.
- Fradeani M, Aquilano A. Clinical experience with Empress crowns. *Int J Prosthodont* 1997;10:241-247.
- El-Mowafy O, Brochu JF. Longevity and clinical performance of IPS-Empress ceramic restorations: A literature review. *J Can Dent Assoc* 2002;68:233-237.
- Gemalmaz D, Ergin S. Clinical evaluation of all-ceramic crowns. *J Prosthet Dent* 2002;87:189-196.
- Hankinson JA, Cappetta EG. Five years' clinical experience with a leucite-reinforced porcelain crown system. *Int J Periodontics Restorative Dent* 1994;14:138-153.