



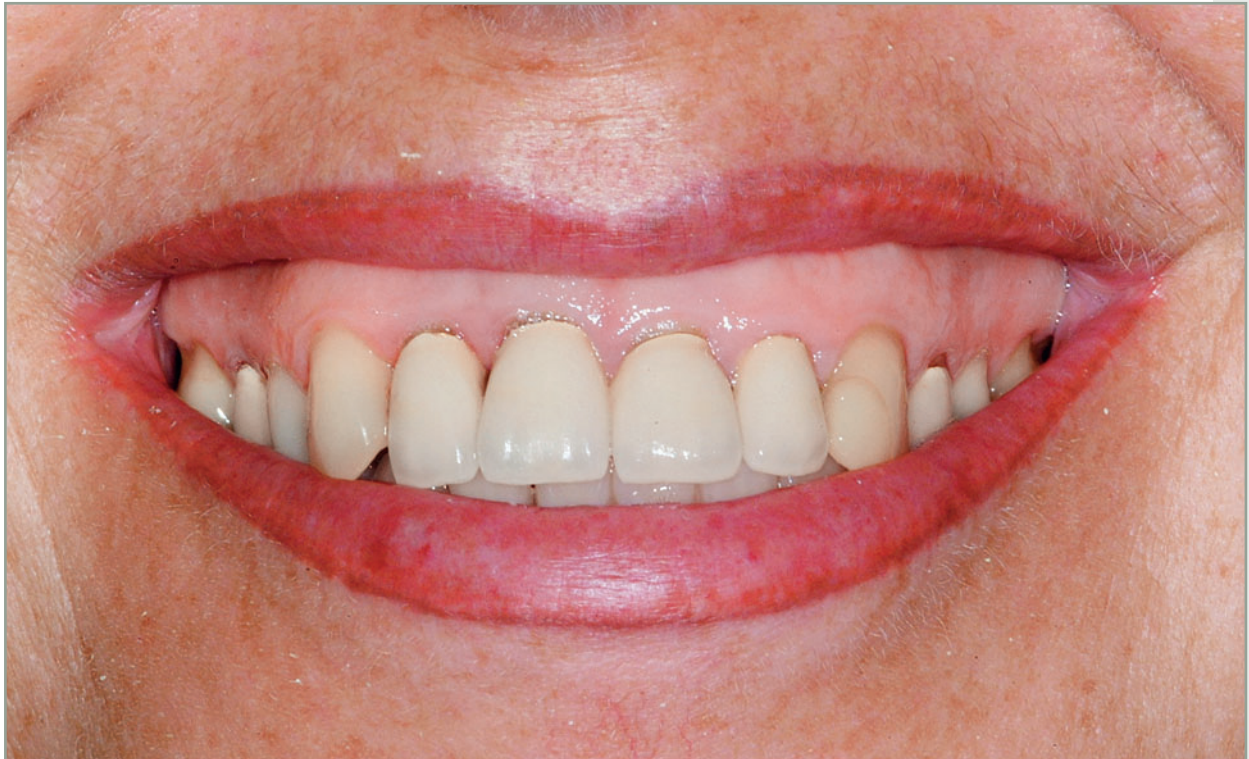Clinical Flexibility of the Metal Free Approach

Davide Cortellini, DDS, Dr Med Dent

Private Practice, Riccione, Italy

Angelo Canale, CDT

Dental Laboratory, Rimini, Italy



Correspondence to: Dr Davide Cortellini

Via I. Nievo 11, 47838 Riccione, Italy;

Tel: +39-541-607193; Fax: +39-54-475434; e-mail: davide.cortellini@fastwebnet.it

Abstract

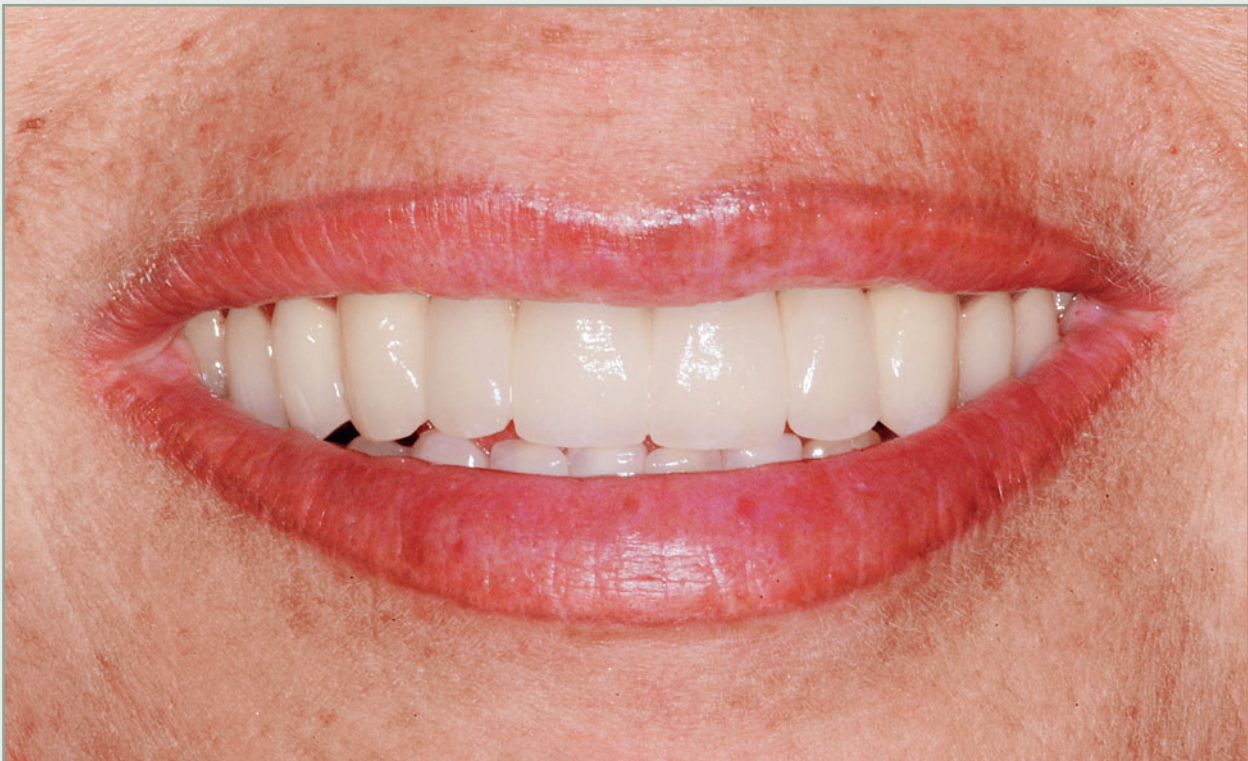The present possibility of defining a plan for reconstructive treatment taking into consideration metal-free materials and related clinical procedures offers wider therapeutic options for the clinician and the dental technician, establishing function, esthetics and longevity in prosthetic rehabilitation.

The metal-free approach may be regarded as a new philosophy of treatment that extends beyond the solution of aesthetic and cosmetic shortcomings in the anterior regions and involves a greater variety of complex clinical cases such as periodontal breakdown conditions and eden-

tulous sites requiring implant therapies with varying degrees of difficulty. Nevertheless, as the use of new metal-free materials is such a recent introduction, there is insufficient long-term evaluation and scientific support available for these to be accepted as an established treatment option.

This article presents two complex prosthetic rehabilitations showing the applicability of the metal-free approach to different clinical conditions including, as well as healthy sites, various patterns of periodontal disease and edentulism.

(Eur J Esthet Dent 2008;3:xxx-xxx.)





Adhesive technologies¹⁻⁴ and high strength metal-free ceramic materials⁵⁻¹⁰ represent fundamentals of modern reconstructive dentistry and are increasingly accepted as a sound choice.

The use of highly resistant 'white-core' structures¹¹⁻¹⁵ is closely related to innovative clinical treatment procedures and, consequently, to a renewed treatment planning concept. Three key points encouraging the clinical application of metal-free restorations, are: they are esthetically pleasing and produce natural-seeming, functional results; they simplify the clinical procedures used and an improved biologic preservation of tooth hard structures, pulp vitality and the periodontal compartment is also seen.¹⁶

Esthetic advantages¹⁷⁻²¹ are mainly due to the structural characteristics of metal-free restorations. These include: translucency ('white-core frameworks' are compatible with a good esthetic level of the soft tissues) and a lack of opaque layers and metal bevels and, eventual consequent gray transparencies in the papilla areas. Furthermore, the decreasing need to sink the prosthetic margins in the intrasulcular compartment makes the achievement of 'pink esthetics' more predictable, contributing to the reduction of incoming signs of gingivitis in predisposed patients.

Biologic benefits of the metal-free approach are essentially derived from the adhesion between ceramic restoration and tooth preparation and from the allocation of prosthetic limits coronally or at the gingival margin level.

These two principal elements allow for: *i*) a greater preservation of residual tooth hard tissues by means of various adhesive restorative solutions alternative to conventional full crowns,^{22,23} such as ceramic onlays and partial crowns; *ii*) the maintenance

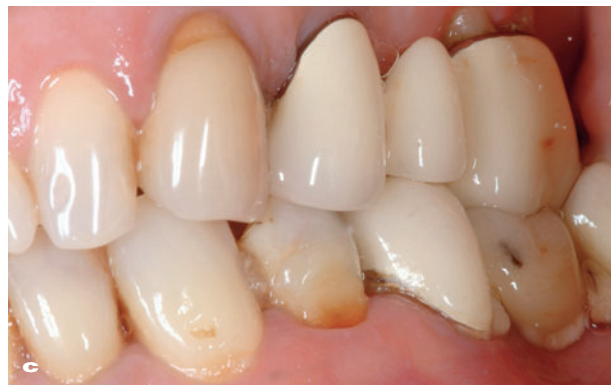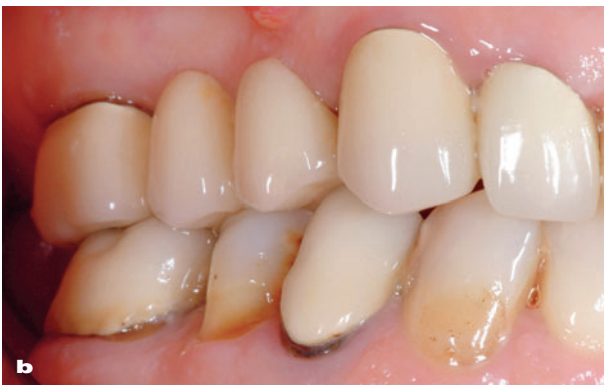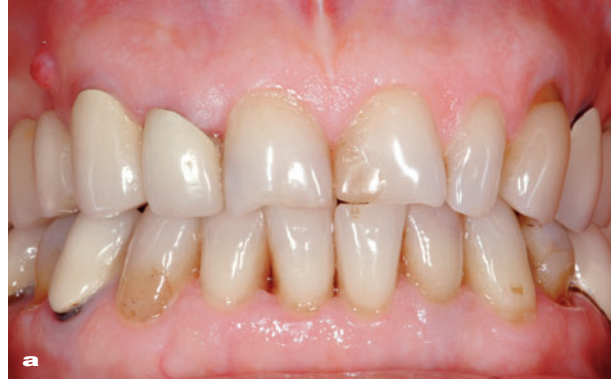of pulp vitality, thanks to a reduced need for intracanal anchorage and consequent endodontic therapies;²⁴ *iii*) a major preservation of periodontal support integrity when an adhesive cementation technique may compensate for scarce retention, thus diminishing the need for surgical crown lengthening;²⁵ *iv*) the maintenance of periodontal health, avoiding invasion of the intrasulcular compartment and making oral hygiene maintenance easier for the patient.^{26,27}

These considerable benefits predispose practical advantages, both for the clinician and the dental technician, who may achieve the final result in a simpler way. These improvements include easier tooth preparation and impression and, consequently, a good degree of precision. A further advantage is represented by the possibility of avoiding complex technical procedures, such as ceramic shoulders, to construct ceramic restorations with excellent esthetic results.

In light of these perceptions the metal-free approach may be regarded as an innovative treatment philosophy, extending beyond the solution of esthetic and cosmetic shortcomings in the anterior regions and, involving a greater variety of complex clinical cases with periodontal breakdown conditions and edentulous sites requiring implant therapies with varying degrees of difficulty. Nevertheless, as the use of new metal-free materials is such a recent introduction, there is insufficient long-term evaluation and scientific support available for this to be accepted as an established treatment option.

This article presents two complex prosthetic rehabilitations showing the applicability of the metal-free approach to different clinical conditions including, besides a healthy patient, various patterns of periodontal disease and edentulism.

Fig 1 Pre-operative clinical appearance of an esthetic dentition: frontal (**a**) and lateral views (**b and c**). A fistula is evident relating to tooth 13. Pre-existing prosthetic restorations were no longer esthetically acceptable. The presence of gingival recessions emphasized the metal bevels. Furthermore, the partial abrasions of maxillary incisal margins, together with a discoloration of resin composite fillings, contributed to the poor appearance of the frontal elements.



Furthermore the peculiarity of the work presented emphasises the flexibility of the different types of metal-free restorations and their adaptability to specific clinical conditions.

Case presentation

Clinical case 1 demonstrated full mouth rehabilitation in the presence of healthy sites and moderate periodontitis utilizing the following metal-free restorations:

- heat-pressed glass-ceramic veneers
- lithium-disilicate reinforced single crowns
- zirconia implant abutments
- zirconia single crowns and fixed partial dentures (FPDs) on natural teeth and implants.

A 50-year-old female patient underwent a dental examination due to complaints of repeated abscesses, the presence of a constant gingival inflammation and a poor esthetic appearance (Figs 1 a to c). The patient's medical history showed that her general condition was good and the patient's request was to solve the acute symptoms and to significantly improve the appearance of her teeth. She also asked for a whiter and more luminous smile.

Clinical examination

Abnormalities, asymmetry or temporomandibular dysfunctions were not evident upon extraoral examination.

Intraoral examination revealed the presence of two fistulae relating to teeth 11 and



13. Pre-existing prosthetic restorations were no longer esthetically acceptable. The presence of gingival recessions ranging between 1 to 3 mm emphasized the metal bevels. The frontal view showed partial abrasions of the maxillary incisal margins, which, together with a discoloration of resin composite fillings, contributed to the poor appearance of the frontal elements. Occlusal examination displayed an intense posterior interference during protrusive movements due to an incorrect alignment of the lower-

left FPD, resulting in an excessive curve of Spee (Fig 1c).

Periodontal examination

The periodontal examination revealed chronic moderate adult periodontitis. The deepest probing depths were localized in the posterior sites, in particular in the maxillary and mandibular left sextants, as shown in Table 1, where values of 6 to 7 mm of

Table 1 Periodontal examination of case 1: probing pocket depth, bleeding on probing, recessions, furcation involvements and tooth mobility.

Upper arch															
	X	16	X	X	13	12	11	21	22	23	24	X	26	X	
Buccal		43 4 • •			23 3 •	33 3	33 3	32 3	32 3	22 3	52 3 •		56 6 •• •		
Palatal		34 3 •			33 4	34 3	43 4 • •	42 2 •	23 2	32 2	22 4 •		55 5 •• •		
Recession		1			1	1					2	2		2	
Mobility															
Lower arch															
	X	46	45	44	43	42	41	31	32	33	34	35	X	37	
Buccal		44 3 •• •	23 2	22 2	23 3	33 4	32 2	32 3	43 4 •	34 2	34 2	35 2 •		24 6	
Lingual		34 3 ••			33 4	34 3	43 4 •	42 2 •	23 2	32 2	22 4 •			55 4 •• •	
Recession		1	2	1	1	1				2	2	1		1	
Mobility															



probing pocket depth (PPD) were detected in conjunction with a furcation involvement of tooth 26. Several sites maintained a healthy condition exhibiting PPD of 2 to 3 mm (maxillary incisors and mandibular frontal elements). Recessions ranging between 1 and 3 mm could be identified in the majority of teeth, mainly in relation to the pre-existing metal-ceramic restorations.

Radiographic examination

A moderate bone loss was mainly localized in the maxillary arch where intrabony defects were visible, especially at the site of tooth 26 (Fig 2). The two fistulae, clinically detected at teeth 12 and 13, corresponded to the radio-transparent areas in proximity of the apex of the same teeth. The incongruous metal post on tooth 12 was clearly evident.

Limited signs of peri-apical inflammation were identifiable in correspondence with root canal-treated teeth 23, 24 and 44. Furthermore, caries lesions could be detected at the following elements: 11, 21, 22, 23, 33, 32, 43, and 45.

Treatment planning and clinical procedures

Taking into consideration the need to treat most of the natural teeth and the desire of the patient for a brighter smile, a complex full mouth prosthetic rehabilitation was proposed.

To correctly define the treatment planning, all teeth were previously classified according to their specific clinical condition to evaluate the eventual incorporation into the final prosthetic reconstruction.

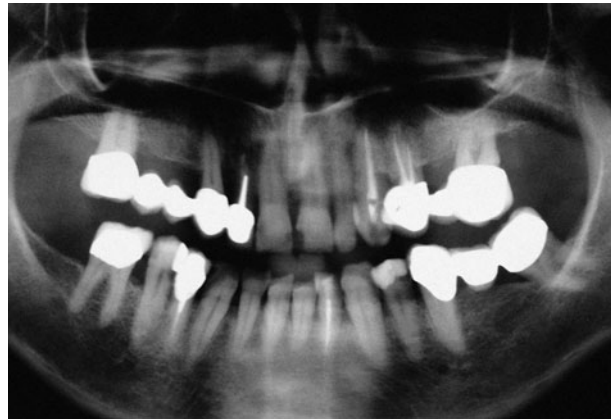

Fig 2 Panoramic radiograph of the initial situation: moderate bone loss was mainly localized to the maxillary arch, where intrabony defects were visible especially at the site of tooth 26. The two fistulae clinically detected at teeth 12 and 13 corresponded to the radio-transparent areas in proximity of the apex of the same teeth. The incongruous metal post on tooth 12 was clearly evident. Limited signs of peri-apical inflammation were identifiable in relation to teeth 23 and 24.

Natural elements were, thus, grouped into three prognostic categories: hopeless, uncertain, and good (Table 2).

The first treatment step consisted of clinical therapy of uncertain teeth to clarify if they could be maintained for the final rehabilitation.

Endodontic therapy was carried out to teeth already prepared underneath the pre-existing restorations that required adjustment of the preparation, or that presented caries infiltration and/or pulp necrosis (16, 13, 26, 37, 35, 45); furthermore previously incongruous root canal treatments were redone (12, 23, 24, 44).

Elements 12 and 13 were subjected to peri-apical surgery for the persistence of fistula lesions after orthograde treatment.

Abutment reconstructions were carried out, according to the metal-free approach, utilizing adhesive systems, fiber-posts and resin composite build-ups to obtain natural



Table 2 Prognosis of natural teeth prior to treatment

	X	16	X	X	13	12	11	21	22	23	24	X	26	X
Hopeless														
Uncertain					
Good						
Good	
Uncertain				.					.					
Hopeless														
	X	46	45	44	43	42	41	31	32	33	34	35	X	37

abutments with chromatic and optical characteristics comparable to a natural tooth.¹⁶

Periodontal surgery was then performed to reduce the PPD in the left maxillary and mandibular sextants.

Tooth 26 was hemisected and the disto-buccal root was extracted to eliminate the II and III degree furcation involvements.

This therapeutic option was justified by the limited bone available at this site, which required a sinus lift procedure for an implant insertion, not accepted by the patient. A new prognostic evaluation of tooth 26 would have been performed at the completion of tissue maturation after surgery.

Once all endodontic and restorative therapies were completed the alternative procedure of implant insertion in the edentulous areas 14, 15, 25 and 36, making all single elements (rather than a recreation of the pre-existing prosthetic scheme, i.e. tooth-supported FPD) was considered.

In the right maxillary quadrant it was decided to create single elements by means of the insertion of two implants at sites 14 and 15. Teeth 13 and 12 were classified as 'uncertain' for endodontic reasons. The

availability of an adequate bone envelope for an easy and predictable implant insertion and the lack of systemic risk factors justified this choice, giving advantages such as a major number of supporting abutments and consequently a diminished mechanical load over weakened natural teeth. Furthermore, the segmentation into single elements could predispose an easier retreatment in case of failure over time. The same decision was taken for the maxillary left quadrant, where the separated roots of tooth 26 were responsible for a poor prognosis of this element as an abutment for a FPD. Nevertheless, in the mandibular left quadrant the previous prosthetic scheme was maintained creating a new FPD. In this case the prognosis of the supporting elements was good and it was decided to avoid, through implant therapy, the introduction of new variables as well as avoiding the added costs for the patient in terms of financial expenses and morbidity.

The provisionals allowed for the elimination of all interferences during protrusive and lateral movements, detectable prior to

treatment, keeping the vertical dimension of occlusion, (which was considered adequate) unchanged.

At the completion of the provisional phase a re-evaluation of all elements was carried out and the typology of the final restorations was established.

Final prosthetic rehabilitation

Figs 3a to c shows the clinical appearance of natural and implant abutments at the completion of endodontic, restorative and surgical therapies. All elements with a poor prognosis showed a good result at the end of the treatment. The final prosthetic scheme consisted of different metal-free restorations selected according to the specific situation (Figs 4a to e, 5) below.

- Maxillary frontal elements (13 to 23): 6 crowns with a lithium disilicate core (IPS e.max press, Ivoclar Vivadent, Liechtenstein). Indications: presence of nonsupporting preparations; highest level of esthetics among all types of core materials; adhesive cementation possible; prosthetic limits at the gingival margin level.
- Mandibular frontal elements (33 to 43): 6 heat-pressed glass-ceramic veneers (IPS Empress Esthetic, Ivoclar). Indications: high level of esthetics; possibility of adjusting color and shape; adhesive cementation.

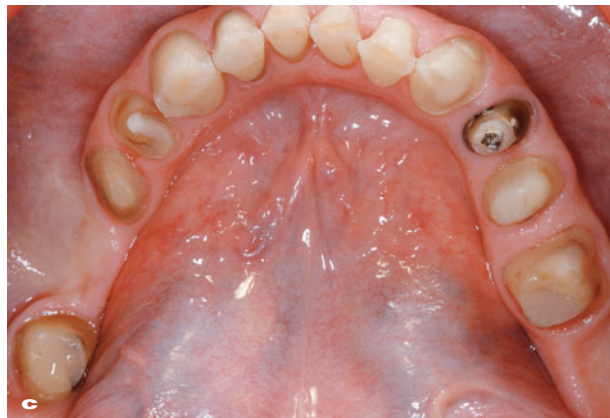
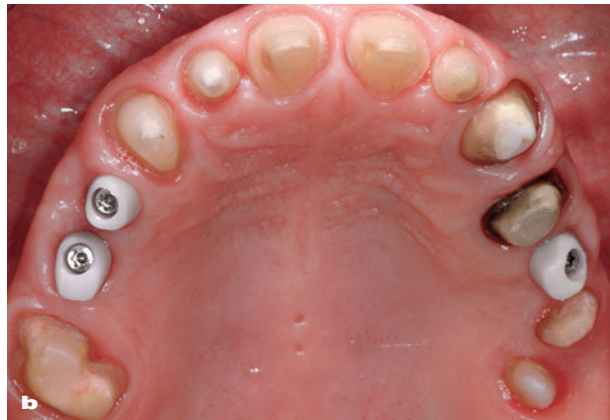
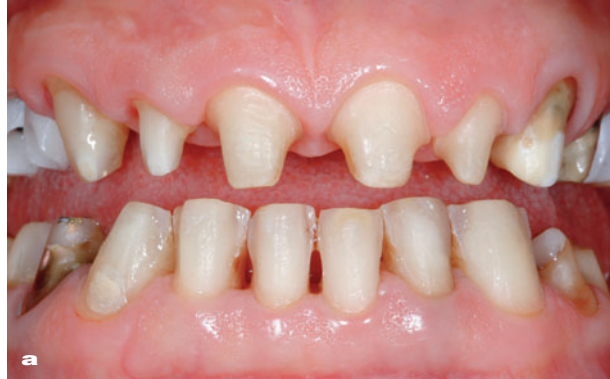Fig 3 Clinical situation at the time of final impressions: frontal (**a**) and occlusal (**b, c**) views of natural and implant abutments. The final prosthetic scheme consisted of different metal-free restorations according to the specific situation: Maxillary frontal elements (13 to 23) were prepared with chamfer-shoulder preparations for 6 lithium-disilicate reinforced crowns; Mandibular frontal elements (33 to 43) exhibit more conservative preparations to directly support 6 heat-pressed glass-ceramic veneers; zirconia abutments were connected to implants in position 14,15 and 25; Posterior elements were prepared with chamfer-shoulder and knife-edge preparations (tooth 16 and hemisected roots of 26), for zirconia single crowns and FPD (37-X-35). Note the discolored teeth 25 and 44.

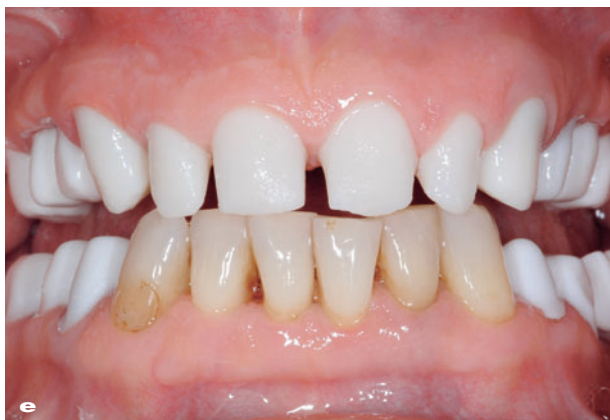
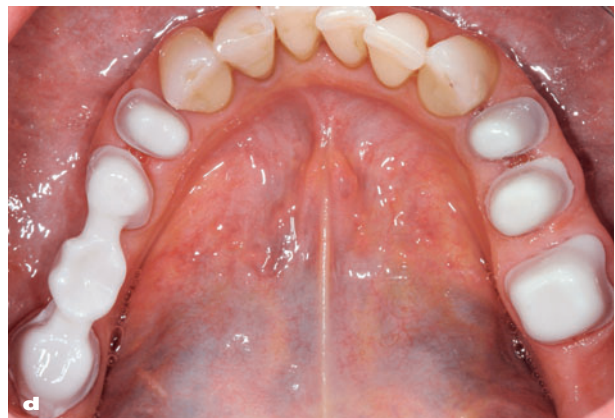
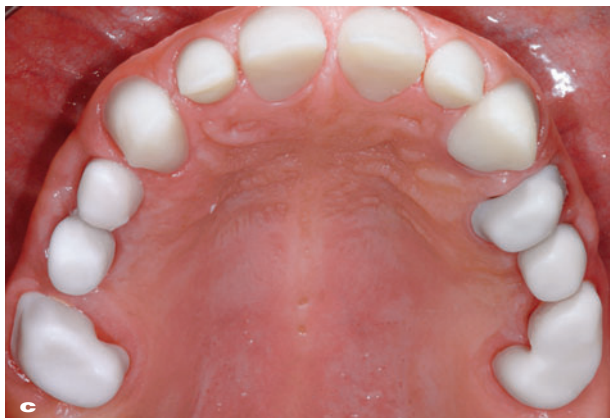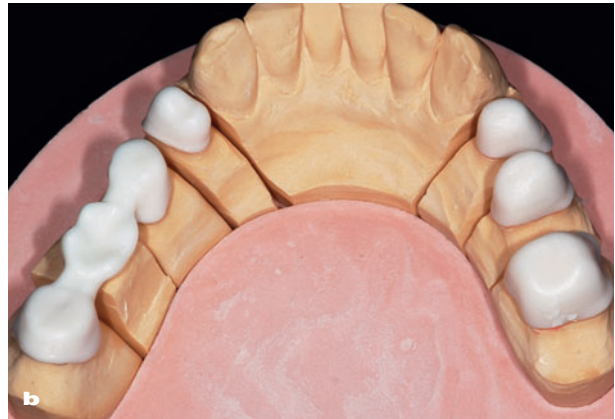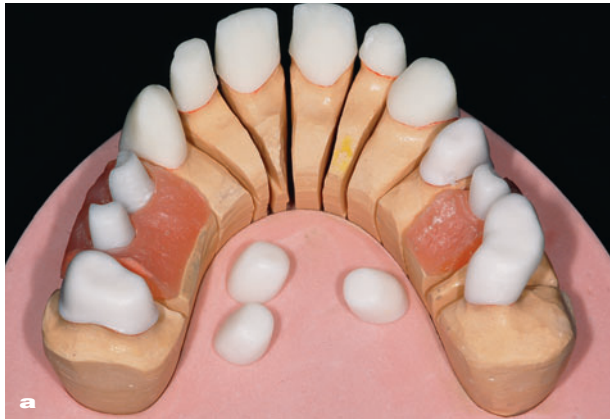Fig 4 Supporting white-cores on the models **(a,b)** and in the mouth **(c, d, e)**. Maxillary frontal cores are made of lithium-disilicate, presenting the highest translucency among the different types of supporting structures. All posterior cores for single crowns, FPD and implant abutments are made of zirconia.

Types of metal-free restorations

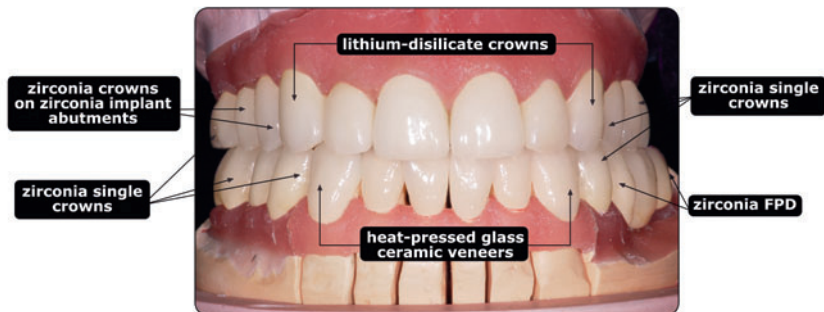

Fig 5 Metal-free restorations completed on the soft tissue cast. The three main types of metal-free restorations were used in the same patient: six lithium disilicate reinforced single crowns (e.max press, Ivoclar Vivident) for the maxillary frontal elements (13 to 23), six heat-pressed glass-ceramic veneers (Empress Esthetic, Ivoclar Vivident) for the lower frontal elements (33 to 43), zirconia implant abutments (14, 15, 25), zirconia single crowns on natural teeth (16, 24, 26, 34, 44, 45, 46), on implant abutments (14, 15, 25) and a 3-element zirconia FPD (37-X-35). The same ceramic material for the veneering (e.max Ceram, Ivoclar Vivident) was used both on the zirconia and lithium disilicate cores, facilitating the achievement of a homogeneous result.

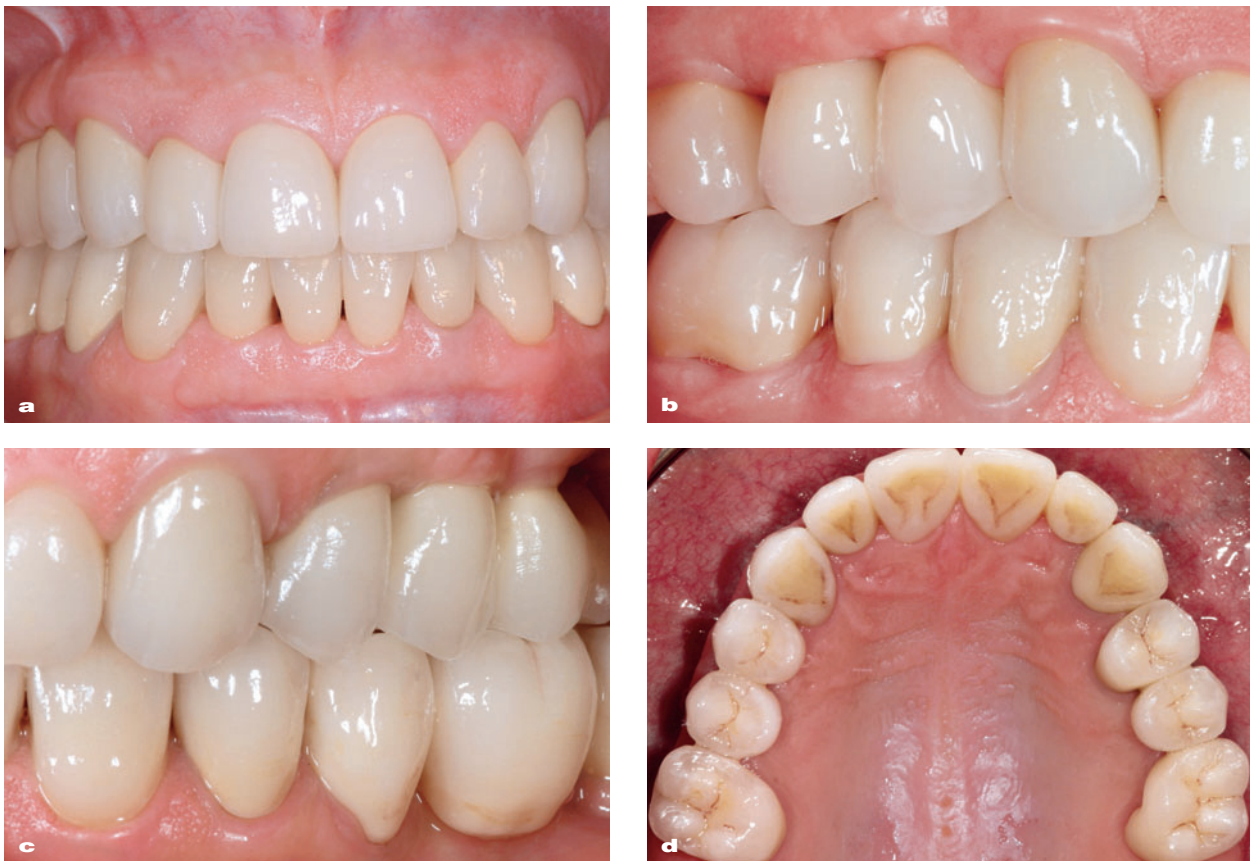

Fig 6 Postoperative clinical views (a to e) of the restored dentition demonstrate tooth vitality and optimum integration. Absence of opaque layers and metal bevels, and a high luminosity, both of the restorations and of gingival tissues, are particularly evident in comparison with the appearance prior to treatment. The good coverage of discolored teeth 25 and 44 by zirconia frameworks is appreciable.

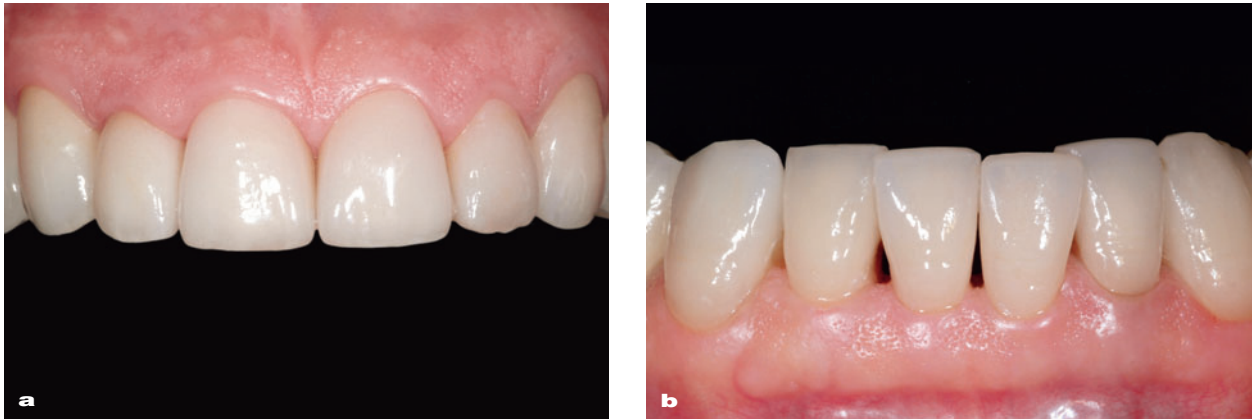

Fig 7 Views of frontal elements emphasize the high level of translucency of maxillary lithium-disilicate reinforced crowns **(a)** and of mandibular pressed glass-ceramic veneers **(b)**. Optimum marginal adaptation associated with a juxtagingival position guarantees a healthy appearance of maxillary and mandibular soft tissues.

- Implant abutments (14, 15, 25): zirconia. Indications: possibility of using all-ceramic crowns; good esthetics and biocompatibility; adequate mechanical strength.
- Posterior elements: zirconia single crowns on natural teeth (16, 24, 26, 34, 44, 45, 46), on implant abutments (14, 15, 25) and a three element zirconia FPD (37-X-35). Indications: high mechanical resistance, compatible with the construction of posterior FPDs; prosthetic margins at the gingival level, good hygienic maintainability and preservation of periodontal health; good esthetic level, both of crowns and

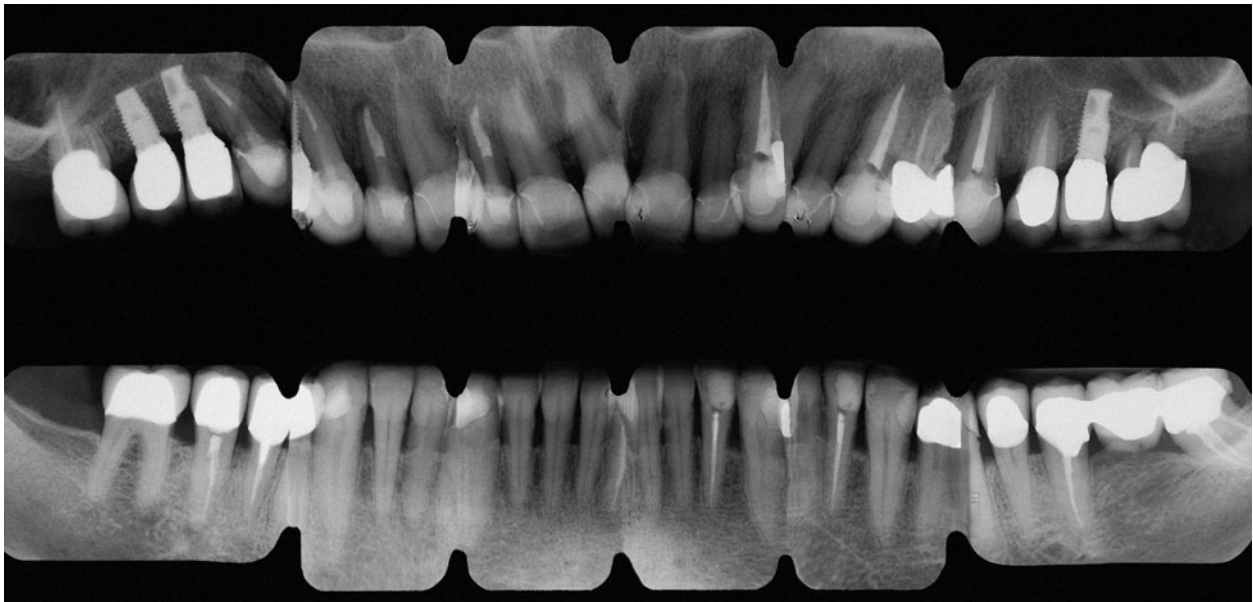


Fig 8 Postoperative radiograph exhibits a good level of precision, appreciable for the different types of metal-free restorations used. The radio-transparency of glass-ceramic and of lithium-disilicate is evident in comparison with the radio-opacity of zirconia structures.

soft tissues; good masking ability on discolored teeth (25 and 44); possibility of using both horizontal and vertical (16 and 26) preparations.

Cementation was performed using resin composite cements. The lower veneers were previously etched with hydrofluoric acid and subjected to a silanisation procedure; at the same time the tooth surface was etched with orthophosphoric acid and conditioned with a dental adhesive avoiding polymerization. Finally, a light-cure resin composite cement was applied (Variolink veneer, Ivoclar Vivident). Lithium-disilicate crowns were etched, silanised and cemented with dual-cure resin cement used also for zirconia restorations (Multilink Automix, Ivoclar Vivident).

The final pictures (Figs 6a to e) show good integration of the restorations with the surrounding tissues. Absence of opaque layers, metal bevels and a high luminosity, both of restorations and of gingival tissues, are particularly evident in comparison with the appearance prior to treatment. The good coverage of discolored teeth 25 and 44 by zirconia frameworks is notable. Views of frontal elements (Fig 7) emphasize the high level of translucency of maxillary lithium-disilicate reinforced crowns and of mandibular pressed glass-ceramic veneers. Optimum marginal adaptation associated with a juxtagingival position guarantees a healthy appearance of maxillary and mandibular soft tissues.

The postoperative radiograph (Fig 8) exhibits a good level of precision, appreciable for the different types of metal-free restorations used. The radio-transparency of glass-ceramic and of lithium-disilicate is evident when compared with the radio-opacity of zirconia structures.

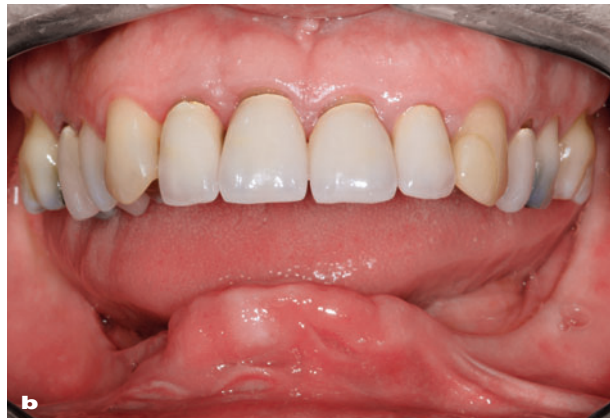
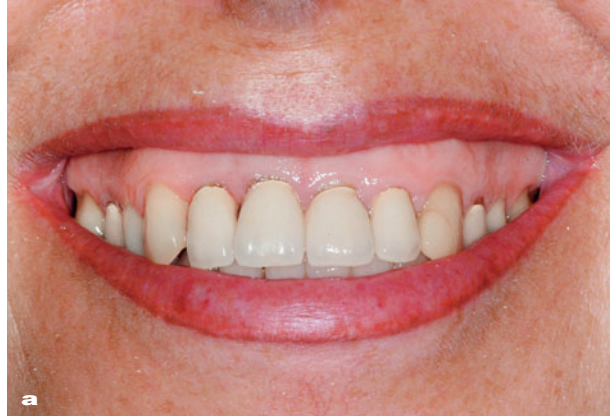
Fig 9 Frontal view of the initial situation: the maxillary arch displayed an esthetically compromised frontal group due to an excessive 'gummy smile' and to failing preexisting crowns (**a**). The lower edentulous arch was characterized by the presence of a thin bone plate at the incisor area (**b**).

Clinical case 2:

Case 2 was a full mouth rehabilitation of an adult chronic periodontitis case associated to an edentulous mandible utilizing the following metal-free restorations:

- a 12-element zirconia tooth supported fixed prosthesis in the maxillary arch
- a 12-element zirconia screw-retained fixed prosthesis on implants in the mandibular arch.



A 50-year-old female patient came to the authors practice for severe functional and esthetic problems with her teeth. The maxillary arch (Fig 9a) displayed an esthetically compromised frontal group due to an excessive 'gummy smile' and to failing pre-existing crowns. The mandibular edentulous arch was characterized by the presence of a thin bone plate at the incisor area and severe atrophy in the posterior zones (Fig 9b). The patient was unhappy with her mobile prosthesis: her main desire was to reestablish fixed mastication and a more agreeable smile.

Clinical examination

The patient's general health was good. Extraoral examination did not reveal abnormalities, asymmetries or temporomandibular dysfunctions. The maxillary incisors were significantly compromised at the intra-oral examination exhibiting a grade I mobility and clinical

signs of deep inflammation. The remaining teeth were better maintained. At the palpation, the edentulous mandible presented a very thin bone plate, especially in the anterior region.

Periodontal examination

The periodontal examination revealed an adult chronic periodontitis with deeper probing depths at the level of incisors. The upper right molar had a grade I buccal furcation, while tooth 26 exhibited grade I buccal, grade II mesio-palatal and grade III disto-palatal furcation involvements (Table 3).

Radiographic examination

Failure of incisors, due to major bone loss, incongruous intracanal posts and a cystic lesion on tooth 12, was radiographically confirmed (Fig 10). Intrabony defects appeared more severe in relation to tooth 26,

Table 3 Periodontal examination of case 2: probing pocket depth, bleeding on probing, recessions, furcation involvements and tooth mobility.

Upper arch														
	X	16	X	X	13	12	11	21	22	23	24	25	26	X
Buccal		54 6 •	53 5 •	54 4 •	33 3 •	67 6 •	77 7 •	78 6 •	66 6 •	54 3 •	52 6 •	44 5 •	64 8 •	
Palatal		64 5 •	44 4 •	54 4 •	33 4 •	66 6 •	67 6 •	76 6 •	66 5 •	43 4 •	45 5 •	44 4 •	55 7 •	
Recession	2	1	1	1	1	1	2	1	1	1	2	2	2	
Mobility						1	1	2	1					

whereas a more horizontal pattern of periodontal support loss could be detected on the remaining elements.

Treatment planning and clinical procedures

A combined perio-prosthetic treatment of the maintained elements splinted through a one-piece fixed prosthesis was considered the better clinical choice for the maxillary arch. Insertion of 6 implants to support a screw-retained full arch fixed prosthesis was the chosen treatment for the mandible. To define the treatment planning all elements were divided, according to their prognosis, into three different categories: hopeless, uncertain, and good (Table 4).

Based on the clinical and radiographic data, a diagnostic waxup was prepared to recreate a normal tooth morphology and proportion, to achieve an acceptable occlusal scheme, as well as to develop a correct prosthetic treatment plan (Fig 11). To optimize overall treatment time the six implants were immediately placed in the interforamina area of the mandibular arch making use of the osteointegration period to treat the elements in the maxillary arch. Due to the thin bone plate an initial vertical bone reduction was carried out in order to gain buccal-lingual thickness. Furthermore,

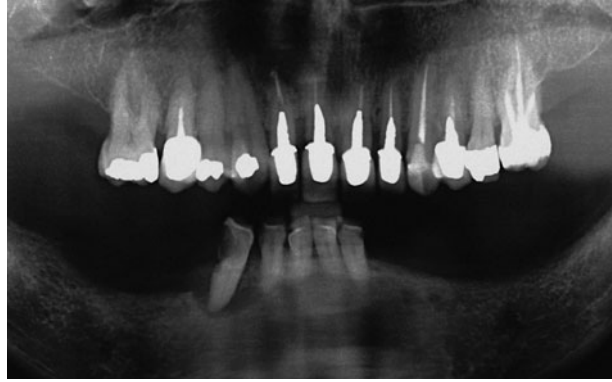

Fig 10 Pre-operative panoramic radiograph: failure of incisors, due to major bone loss, incongruous intra-canal posts and a cystic lesion on tooth 12, are appreciable. Intra-bony defects appeared more severe in correspondence to tooth 26, whereas a more horizontal pattern of periodontal support loss can be detected on the remaining elements.

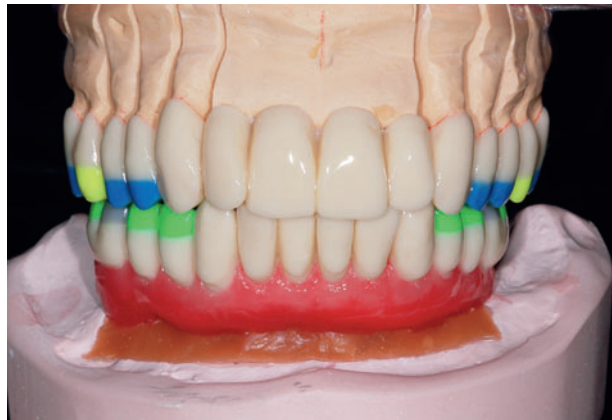

Fig 11 Based on the clinical and radiographic data, a diagnostic waxup was prepared to recreate a normal tooth morphology and proportion, to achieve an acceptable occlusal scheme, as well as to develop a correct prosthetic treatment plan.

Table 4 Prognosis of natural teeth prior to treatment.

	X	X	16	15	14	13	12	11	21	22	23	24	25	26	X	X
Hopeless							•	•	•	•						
Uncertain				•							•	•		•		
Good			•		•	•							•			

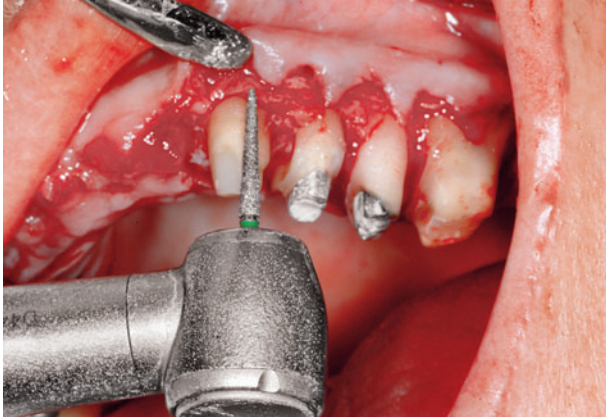


Fig 12 The patient was subjected to periodontal surgery for PPD reduction and correction of anatomical deficiencies created by the disease. Regularization of bone architecture by means of osteoplasty, intraoperative abutment preparation and apical flap repositioning helped to restore periodontal health, although with reduced attachment support.

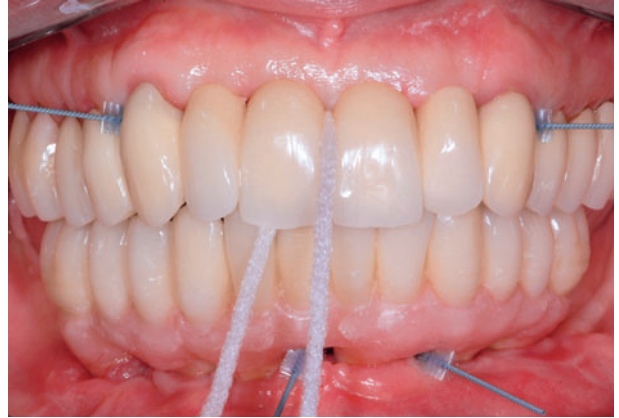

Fig 13 At the completion of osteointegration and preliminary soft tissue healing the second provisional restorations were placed. Adequate interdental spaces were provided to allow for efficient mechanical plaque control by the patient.

bone substitutes (Bio-Oss[®], Osteohealth[®] NY, USA) in conjunction with resorbable membranes were positioned both on the buccal and on the lingual cortical walls to increase the scarce bone envelope, which was responsible for the partial transparency of the implants after insertion.

All vital teeth were previously endodontically treated in order for periodontal surgery and intraoperative preparations avoiding excessive clinical sensitivity or successive necrosis to be carried out.

Retreatment and fiber post build-ups were performed where possible. The four incisors were extracted and a provisional was placed. The patient was then subjected to periodontal surgery for PPD reduction and correction of anatomical deficiencies created by the disease (Fig 12). Regularization of bone architecture by means of osteoplasty, intraoperative abutment preparation and apical flap repositioning helped to restore periodontal health, although with reduced attachment

support. At the completion of osteointegration and preliminary soft tissue healing, after 3 months, the second provisional restorations were placed (Fig 13). The overall duration of the provisional phase was 9 months so as to effectively evaluate the final prognosis of the treated natural elements, the acceptability of the new occlusal scheme, and to permit complete tissue maturation.

At the second reevaluation all teeth exhibited good prognosis with no pathological probing depths or peri-apical lesions.

The patient's occlusal scheme was well tolerated with no detectable clinical symptoms of interferences or parafunctions.

Final prosthetic rehabilitation

The prosthetic treatment of cases with a partial reduction of periodontal support should envisage therapeutic splinting of

all natural abutments. Similarly, interforamina implants require a connection in order to support a full arch screw-retained fixed prosthesis.

Thus, the option of utilizing white-core frameworks as an alternative to metal-alloy structures was considered in order to evaluate the applicability of the metal-free approach to complex clinical situations. However, it should be noted that the type of fixed prostheses chosen was introduced only recently, and that, consequently, documentation is scarce. Therefore, this does not, at present, represent the most predictable type of treatment.

Two definitive impressions of the maxillary arch were taken using a polyether material (Impregum™, Penta, 3M ESPE, MN, USA) on custom impression trays. An impression plaster was used for the implant in the mandible (Fig 14). The record of the desired maxillo-mandibular relationship was obtained taking three waxes for the centric relation and three waxes for the cross mounting. A waxup of the final restoration was completed and subsequently reduced, creating the necessary space for the veneering material and, thus, defining the correct volumes of the supporting framework.

A double scan was performed for the maxillary arch: first the natural abutments and then the wax framework were scanned and a file corresponding to the framework shape and thickness to guarantee a correct ceramic support was obtained. This file had been previously transformed into a polyamide model to try in the mouth before the final conversion into a zirconia structure (Figs 15 a and b). In the mandible a resin composite framework was first created and then scanned to construct a Procera® Implant Bridge (PIB, Nobel Biocare, Sweden).

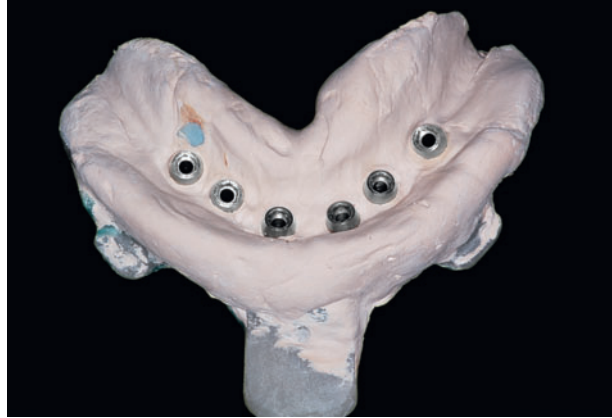

Fig 14 A plaster impression for the implants was made, whereas a polyether material was used for natural abutments.

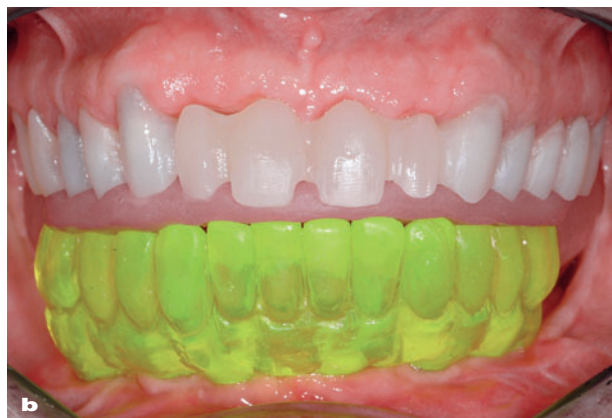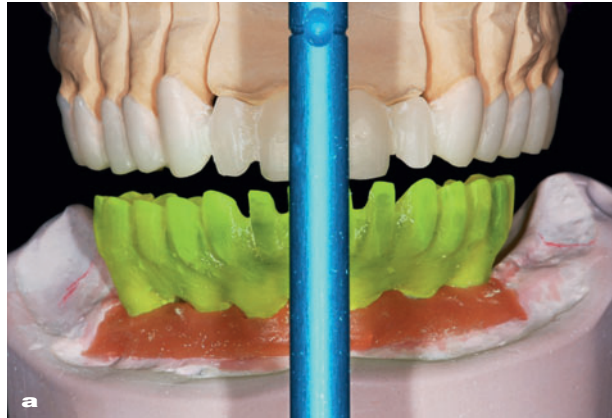


Fig 15 Polyamide model on natural abutments and resin composite model on implants positioned in the maxillary, and in the mandibular arch respectively, in the articulator (a) and in the mouth (b) to check precision before the final conversion into zirconia structures.

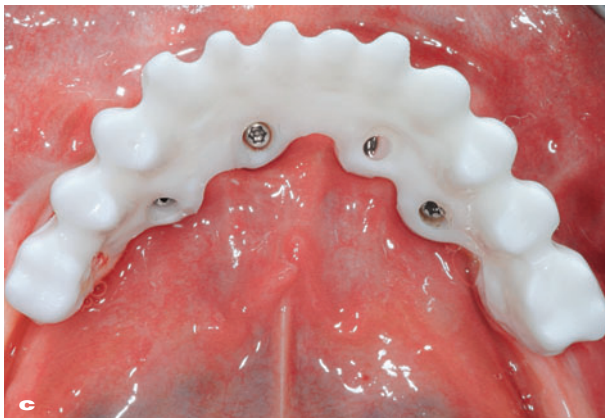
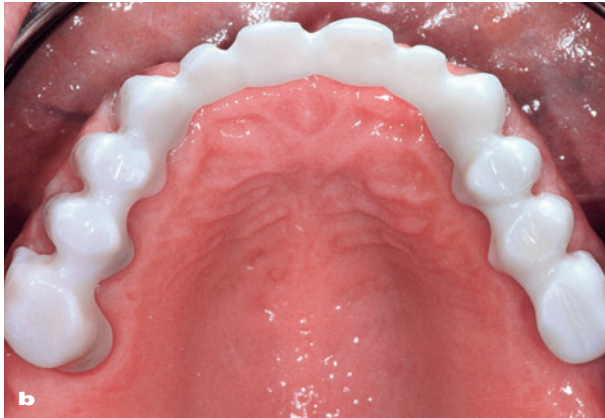
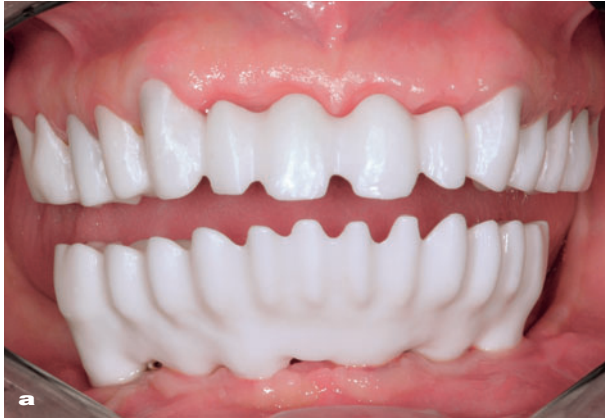Fig 16 The definitive 12-element zirconia structures (**a to c**) obtained from the milling centres were tried to check the precision, relation with soft tissues, correct ceramic support and occlusal relation.

Subsequently the definitive structures were obtained from the milling centers and tried out to check precision, relation to soft tissues, correct ceramic support and occlusal relation (Figs 16 a to c).

Once the ceramic veneering was completed (IPS e.max Ceram, Ivoclar Vivident) and checked (Fig 17) the maxillary zirconia fixed prosthesis was cemented utilizing a dual-resin cement (Multilink Automix, Ivoclar Vivident). The lower PIB was screwed directly onto the heads of the fixtures.

The final pictures (Figs 18a to e) show the completed rehabilitation. Good integration with the soft tissues is evident, showing a healthy appearance of soft tissue in contact with zirconia. The prosthetic margins in the maxillary arch are located at the gingival level. The zirconia PIB incorporates a consistent pink band to compensate for the severe vertical bone loss. The initial gummy smile was partially corrected through periodontal surgery and the overall esthetic result of zirconia fixed prosthesis may be considered good. The

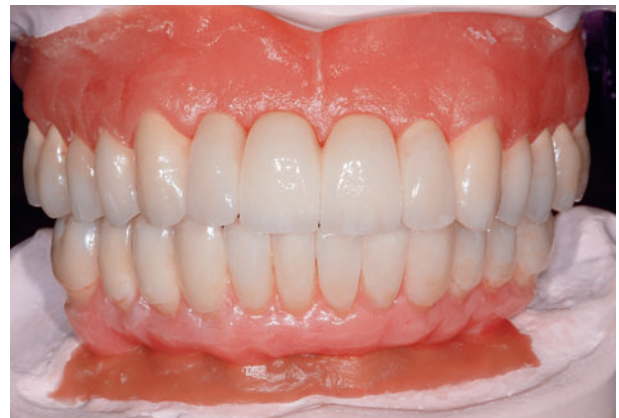

Fig 17 Completed metal-free prostheses on soft tissue casts. The lower 12-element fixed prosthesis incorporates a pink band to compensate for the severe loss of alveolar structure.

natural appearance of zirconia restorations (Fig 19a) is evident, resulting in a pleasant smile (Fig 19b) and good periodontal health due also to the juxtagingival margins. The postoperative radiograph exhibits good precision of the 12-element zirconia fixed prosthesis (Fig 20).

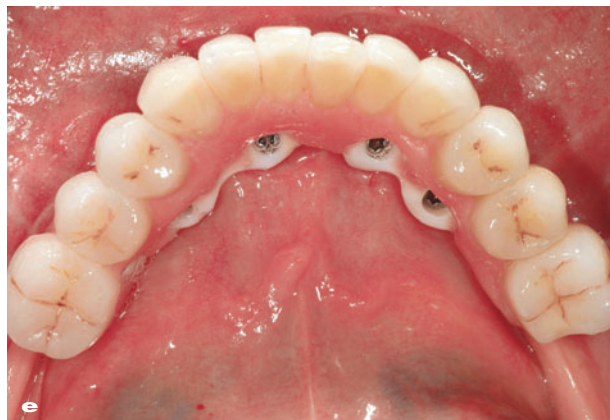
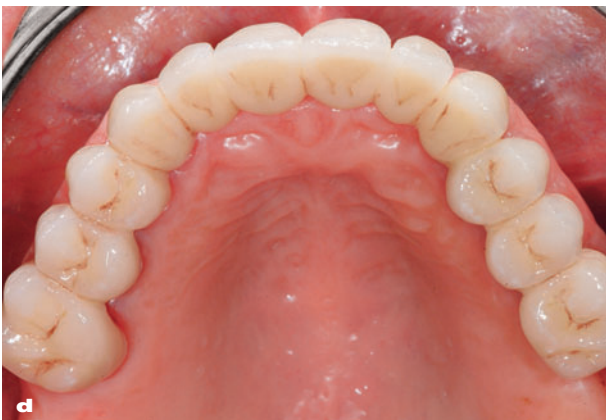
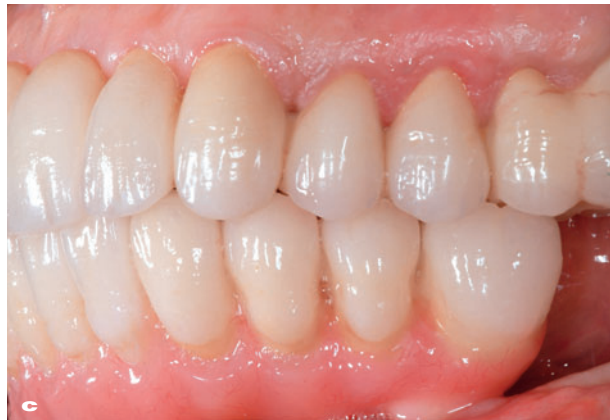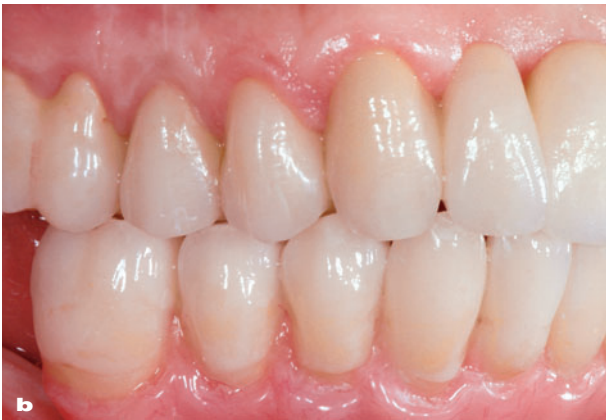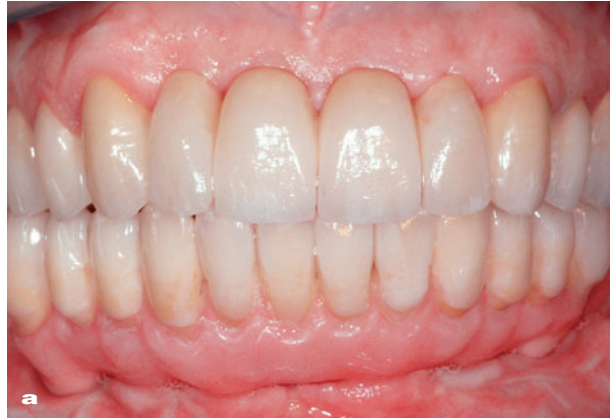Fig 18 The final pictures (a to e) show the completed rehabilitation. It is evident that there is good integration with the soft tissues showing a healthy appearance in contact with zirconia. The prosthetic margins in the maxillary arch are located at the gingival level.

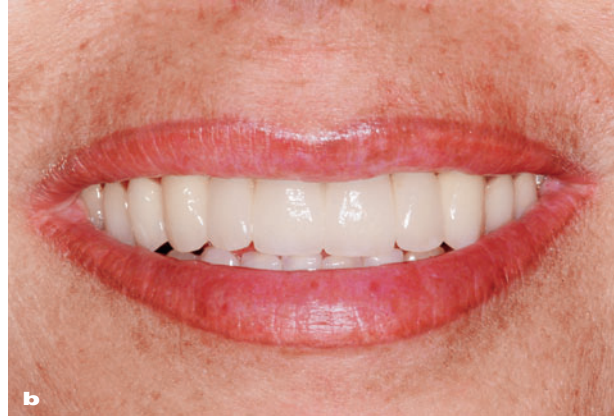
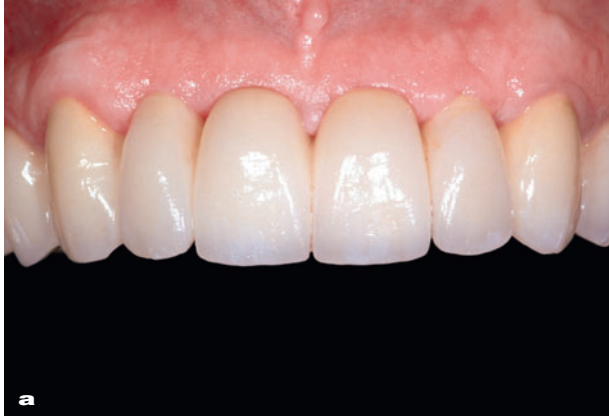
Fig 19 The overall aesthetic result of zirconia fixed prostheses may be considered good. The natural appearance of zirconia restorations (**a**) is evident, resulting in a pleasant smile (**b**) and good periodontal health due also to the juxtagingival margins.

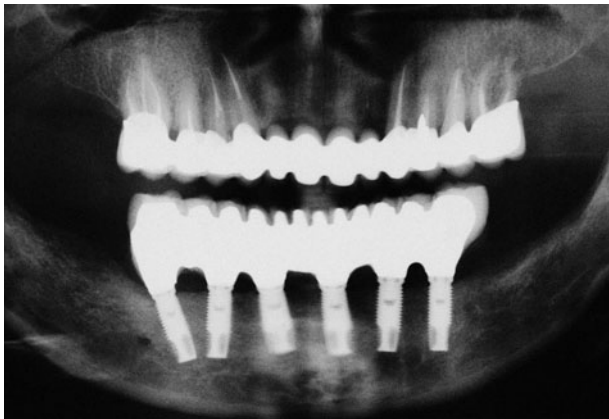

Fig 20 The postoperative radiograph exhibits good precision of the 12-element zirconia fixed prostheses.

Conclusion

The two clinical cases presented demonstrate the adaptability of the metal-free approach to different clinical situations, besides the treatment of esthetic zones with intact periodontium. The two rehabilitation procedures show how these restorations may be also used for posterior sites, discolored elements, periodontally involved teeth and edentulous areas.

The clinician and the technician should be able to select from the various metal-free materials the most suitable for each specific clinical situation, so as to optimize the final outcome of prosthetic therapy. This concept is clearly emphasized in the first case, where the three main types of metal-free materials: heat-pressed glass-ceramic; lithium-disilicate and zirconia, coexist in the same patient. The veneering process was carried out utilizing a single ceramic material (IPS e-max Ceram, Ivoclar Vivident) for the two different cores, which contributed in simplifying the achievement of the final result.

As reported in a previous paper by the authors,¹⁶ the indications for the 3 types of restorations, are as follows.

- Frontal teeth with supporting preparations: heat-pressed glass-ceramic (mandibular veneers 33 to 43, case 1)
- Frontal teeth with nonsupporting preparations: lithium-disilicate reinforced restorations (single maxillary crowns 13 to 23, case 1)
- Posterior elements with adequate retention, discolored teeth, implant abutments and zirconia restorations (all posterior elements in case 1, all elements in case 2).



Generally the highly translucent metal-free materials were used for anterior sites, whereas zirconia was chosen for the posterior areas. Exceptions to this conventional indication were discolored teeth located in the anterior region that required a zirconia core for its masking ability; a further exception is represented by posterior scarcely retentive natural abutments, which may need an adhesive cementation procedure and a lithium-disilicate etchable core restoration (when an apical positioned flap can be avoided). The mechanical strength of a lithium-disilicate core is adequate for the manufacturing of single posterior crowns.

The second relevant difference between the two cases is represented by the segmentation of the prosthetic reconstruction:

- all single elements in the maxillary arch of case 1
- two splinted full-arch fixed prostheses in case 2.

Segmentation of long span FPDs via implant insertion simplifies the application of metal-free restorations.¹⁶ In cases where pre-existing FPDs have to be redone, the option of implant insertion and the creation of single crowns should be based on careful evaluation of the long-term prognosis of the natural abutments to support a further FPD, compared with the predictability of possible implant therapy at that specific site.

In case 1 the creation of all single elements was carried out for the maxillary arch: the presence of previous intracanal posts, the function of these elements as supporting abutments for many years, balanced with an easy and affordable implant therapy in that area, made this option the most suitable.

Nevertheless, in periodontal cases the connection through an undivided fixed prosthesis of those elements subjected to osteoplasty and apically repositioned flaps for pocket elimination is essential for compensating the partial reduction of periodontal support, thus prolonging the life of natural abutments.²⁸ The same prerequisite is needed if six interforamina implants need to be restored. The second clinical case is an example where metal-free restorations were used connecting all natural abutments in the maxillary arch and all implant abutments in the mandible.

Regardless of the clinical and therapeutic divergences of the two treated cases some common chief advantages may be pointed out:

- esthetically pleasing, natural-looking results
- margins allocated at the gingival level
- preservation of periodontal health
- high biocompatibility
- high retention for etchable ceramics.

Although the use of metal-free restorations in daily practice seems to provide affordable results, the long-term behavior of the new ceramic materials is still scarcely known,²⁹⁻³⁸ mainly because of their recent introduction and the continuing improvement of materials and manufacturing systems. Consequently, at present, more established prosthetic solutions, such as conventional metal-ceramic fixed prostheses, would probably represent a more predictable type of treatment for the second case illustrated.

Two recent systematic literature reviews have analyzed all published studies addressing the survival and complication rate of metal-free single crowns and FPDs in relation to metal-ceramic crowns.^{39,40} All-



ceramic crowns exhibited a 5-year survival rate comparable to that seen for metal-ceramic crowns (93.3% versus 95.6%). In particular, in the anterior regions, the survival rate was comparable for all-ceramic and metal-ceramic crowns, whereas in the posterior sites this issue was true only for the core-reinforced types of restorations (lithium-disilicate 93.7%).

Among the main biologic complications, loss of pulp vitality was similar for all-ceramic and metal-ceramic crowns with a 5-year rate of 2.1%. The 5-year rates of dental decay were lower for all-ceramic crowns compared with metal-ceramic (1.8% versus 3.2%). The 5-year rates of crowns lost for periodontitis was also lower for all-ceramic crowns compared with metal-ceramic restorations (0% versus 0.6%).

The main technical complication for all-ceramic single crowns was the fracture of the core, whereas the incidence of ceramic chipping was lower for all-ceramic (3.7%) than for metal-ceramic crowns (5.7%).

Compared with metal-ceramic FPDs, metal-free FPDs exhibited biologic complication trends similar to those observed for single crowns. Nevertheless, the technical complications were significantly higher for metal-free FPDs, which presented (with the exception of zirconia) high rates of framework fractures.

This evidence emphasizes the necessity of using zirconia framework for the construction of FPDs. The second important technical complication observed, further demonstrated by a 5-year prospective study on zirconia FPDs,⁴¹ was limited or extensive fractures of the veneering material. This might be explained by the need to improve the mechanical-physical properties of the veneering ceramics and/or by an insufficient support through the frame-

work. However, it should be considered that materials and manufacturing systems are constantly improving and at present they guarantee superior mechanical and clinical performance compared with the materials and techniques analyzed in the studies. Taking into consideration the concepts presented by these works, in conjunction with the authors' experience, some key points for the long-term success of metal-free restorations, both clinical and technical, are outlined below; their observation might contribute to reducing the complication rates of the metal-free approach.

- Utilize the different metal-free materials according to the correct indications.
- Tooth preparation: provide a minimal occlusal space of 1.5 mm. Avoid sharp angles and irregularities.
- Heat pressed glass-ceramics and lithium disilicate restorations should always be adhesively cemented. The procedure should include an etching step with hydrofluoric acid followed by the application of a silane; the natural abutment should be treated with an enamel-dentin adhesive. Finally a resin composite cement should be used.
- Perform a precise and careful occlusal balance to eliminate all interferences and to fine-tune the steepness of the guides.
- Zirconia frameworks should be designed to provide adequate support of the veneering material.
- Trying the designed structure using resin composite or polyamide models might be helpful in evaluating the project tridimensionally and to identify eventual major defects of the fitting. Precision and accuracy should be checked on the final zirconia structure.



The two clinical cases demonstrate how the metal-free approach may represent a reconstructive philosophy that could potentially be addressed to almost all clinical situations in fixed prosthodontics. If the use of metal-free restorations is currently considered reliable for limited reconstructive cases, the possibility of undertaking treatment of complex situations through this approach should be carefully examined by the clinician and the technician considering the need for a proper follow-up period of the new materials, and for

sound scientific documentation, which remains essential to promote a conventional application of the metal-free approach.

Acknowledgements

The authors would like to thank Dr Arnaldo Castellucci, Florence, for the peri-apical surgery in case one, and Dr Manlio Gessaroli, Maxillo-Facial Department, Bufalini Hospital, Cesena, for the implant surgery in case two.

Very special thanks also to Angela Giordano, Barbara Bergantini, Daniela Bergantini and Claudio Rivolta of the Dental Laboratory Angelo Canale for their contribution to the prosthetic work.

References

- Blatz MB, Sadan A, Kern M. Resin-ceramic bonding: a review of the literature. *J Prosthet Dent* 2003;89:268–74.
- Sadan A, Blatz MB, Soignet D. Influence of silanization on early bond strength to sand-blasted densely sintered alumina. *Quintessence Int* 2003;34(3):172–6.
- Burke FJ, Fleming GJ, Nathanson D, Marquis PM. Are adhesive technologies needed to support ceramics? An assessment of the current evidence. *J Adhes Dent* 2002;4(1):7–22.
- Fleming GJ, Maguire FR, Bahmra JG, Burke FM, Marquis PM. The Strengthening Mechanism of Resin Cements on Porcelain Surfaces. *J Dent Res* 2006;85(3):272–276.
- Marquadt P, Strub JR. Survival rate of IPS empress 2 all-ceramic crowns and fixed partial dentures: results of a 5 year prospective clinical study. *Quintessence Int* 2006;37(4):253–259.
- Van Dijken JWV. All-Ceramic Restorations: Classification and Clinical Evaluations. *Compend Contin Educ Dent* 1999;20(12):1115–24, 1126 passim; quiz 1136.
- Touati B. Innovative dental ceramics: expanding the material alternatives. *Pract Proced Aesthet Dent* 2005;17(5):357–8.
- Brodbeck U. Xawex Zirconia- a new framework material for CAD-CAM All Ceramic Dental Restorations. *Quintessenz* 2005;56(4):407–420.
- Vult von Steyern P. All-ceramic fixed partial dentures. Studies on aluminum oxide-and zirconium dioxide-based ceramic systems. *Swed Dent J Suppl* 2005;(173):1–69.
- Luthardt RG, Sandkhul O, Reitz B. Zirconia-TZP and alumina-- advanced technologies for the manufacturing of single crowns. *Eur J Prosthodont Restor Dent* 1999;7(4):113–119.
- Besimo CE, Spielman HP, Rohner HP. Computer-assisted generation of all-ceramic crowns and fixed partial dentures. *Int J Comput Dent* 2001;4(4):243–262.
- Kurbad A. Clinical aspects of all-ceramic CAD/CAM restorations. *Int J Comput Dent* 2002;5(2-3):183–97.
- Raigrodsky AJ. Contemporary all-ceramic fixed partial dentures: a review. *Dent Clin North Am* 2004;48(2):VIII, 531–44.
- Liu PR. A panorama of dental CAD/CAM restorative systems. *Compend Contin Educ Dent* 2005;26(7):507–8, 510, 512 passim; quiz 517, 527.
- Schweiger M, Höland W. IPS Empress 2 a new pressable high-strength glass ceramic for aesthetic all ceramic restorations. *Quint Dent Technol* 1999;22:143–151.
- Cortellini D, Valenti M, Canale A. The Metal-Free Approach to Restorative Treatment Planning. *Eur J Esthet Dent* 2006;1:230–247.
- Touati B, Miara P, Nathanson D. *Aesthetic Dentistry and Ceramic Restorations*. Martin Dunitz Ltd 1999.
- Magne P, Douglas WH. Rationalization of aesthetic restorative dentistry based on biomimetics. *J Esthet Dent* 1999;11(1):5–15.
- Raptus NV, Michalakis KX, Hirayama H. Optical behavior of current ceramic systems. *Int J Periodontics Restorative Dent* 2006 Feb;26(1):31–41.
- Aoshima H. Aesthetic all-ceramic restorations: the internal live stain technique. *Pract Periodontics Aesthet Dent* 1997 Oct;9(8):861–8; quiz 870.



21. McLean JW. Evolution of dental ceramics in the twentieth century. *J Prosthet Dent*. 2001 Jan;85(1):61-6. Review. Erratum in: *J Prosthet Dent* 2001;85(4):417.
22. Edelhoff D, Sorensen A. Tooth structure removal associated with various preparations designs for posterior teeth. *Int J Periodontics Restorative Dent* 2002;22:241-249.
23. Magne P, Douglas WH. Porcelain veneers: dentin bonding optimization and biomimetic recovery of the crown. *Int J Prosthodont*. 1999;12(2):111-21.
24. Cortellini D, Parvizi A. Rehabilitation of severely eroded dentition utilizing all-ceramic restorations. *Pract Proced Aesthet Dent*. 2003;15(4):275-82; quiz 284.
25. Cortellini D, Canale A, Giordano A, Bergantini B, Bergantini D. The combined use of all-ceramic and conventional metal-ceramic restorations in the rehabilitation of severe tooth wear. *Quint Dent Technol* 2005;28:205-214.
26. Smukler H, Chaibi M. periodontal and clinical considerations in clinical crown extension: A rational basis for treatment. *Int J Periodontics Restorative Dent* 1997; 17:464-477.
27. Reitemeier B, Hansel K, Walter MH, Kastner C, Toutenburg H. Effect of posterior crown margin placement on gingival health. *J Prosthet Dent* 2002; 87:167-172.
28. Kourkouta S, Hemmings KW, Laurell L. Restoration of periodontally compromised dentitions using cross-arch bridges. Principles of perio-prosthetic patient management. *Br Dent J* 2007;25:203(4):189-95.
29. Fradeani M. Six year follow-up with empress veneers. *Int J Periodontics Restorative Dent*. 1998;18(3):216-225.
30. Van Gogswaardt DC, Van Thoor W, Lampert F: Clinical assessment of adhesively placed ceramic veneer after 9 years. *J Dent Res*. 1998;(77):779.
31. Fradeani M, Redemagni M. An 11-year clinical evaluation of leucite-reinforced glass-ceramic crowns: a retrospective study. *Quintessence Int*. 2002;33(7):503-10.
32. Zarone F, Sorrentino R, Vaccaro F, Russo S, De Simone G. Retrospective clinical evaluation of 86 Procera AllCeram anterior single crowns on natural and implant-supported abutments. *Clin Implant Dent Relat Res*. 2005;7 Suppl 1:S95-103.
33. Odman P, Andersson B. Procera AllCeram crowns followed for 5 to 10.5 years: a prospective clinical study. *Int J Prosthodont*. 2001 Nov-Dec;14(6):504-9.
34. Fradeani M, D'Amelio M, Redemagni M, Corradi M. Five-year follow-up with Procera all-ceramic crowns. *Quintessence Int*. 2005 Feb;36(2):105-113.
35. Malament KA, Socransky SS, Thompson V, Rekow D. Survival of glass-ceramic materials and involved clinical risk: variables affecting long-term survival. *Pract Proced Aesthet Dent*. 2003;Suppl:5-11.
36. Blatz MB. Long term clinical success of all-ceramic posterior restoration. *Quintessence Int* 2002;33:415-426.
37. Fradeani M, Aquilano A. Clinical Experience with IPS Empress Crowns. *Int J Prosthodont* 1997;10:241-247.
38. Suarez MJ, Lozano JF, Paz Salidol M, Martinez F. Three year clinical evaluation of In-Ceram Zirconia posterior FPDs. *Int J Prosthodont* 2004;17(1):35-8.
39. Sailer I, Pjetursson BE, Zwahlen M, Hammerle CHF. A systematic review of the survival and complication rates of all-ceramic and metal-ceramic reconstructions after an observation period of at least 3 years. Part I: single crowns. *Clin. Oral Impl. Res*:18(Suppl. 3),2007;73-85.
40. Sailer I, Pjetursson BE, Zwahlen M, Hammerle CHF. A systematic review of the survival and complication rates of all-ceramic and metal-ceramic reconstructions after an observation period of at least 3 years. Part II: fixed dental prostheses. *Clin Oral Impl. Res*: 18(Suppl. 3) 2007;86-96.
41. Sailer I, Feher A, Filser F, Gauckler LJ, Luthy H, Hammerle CH. Five-year clinical results of zirconia frameworks for posterior fixed partial dentures. *Int J Prosthodont*.: 2007;20(4):383-388.

Copyright ©
Not for Publication
Quinnessence

